



Aerospace Medicine Institute “Angelo Mosso” Milan, Italy

- Department of Cardiology



Italy Air Force





Bicuspid Aortic Valve Disease accidentally discovered in military pilots: single command, multi-crew or surgery?

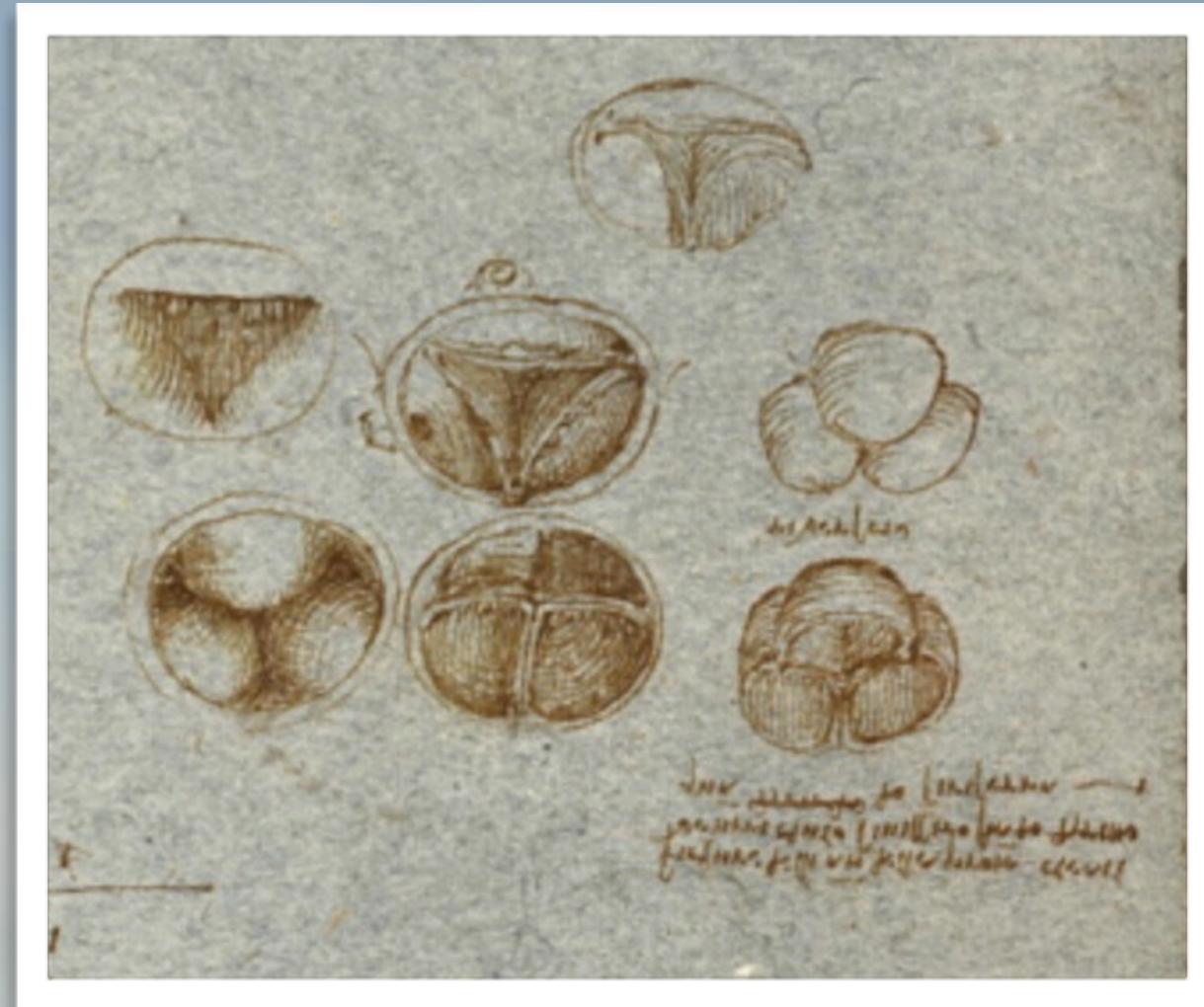
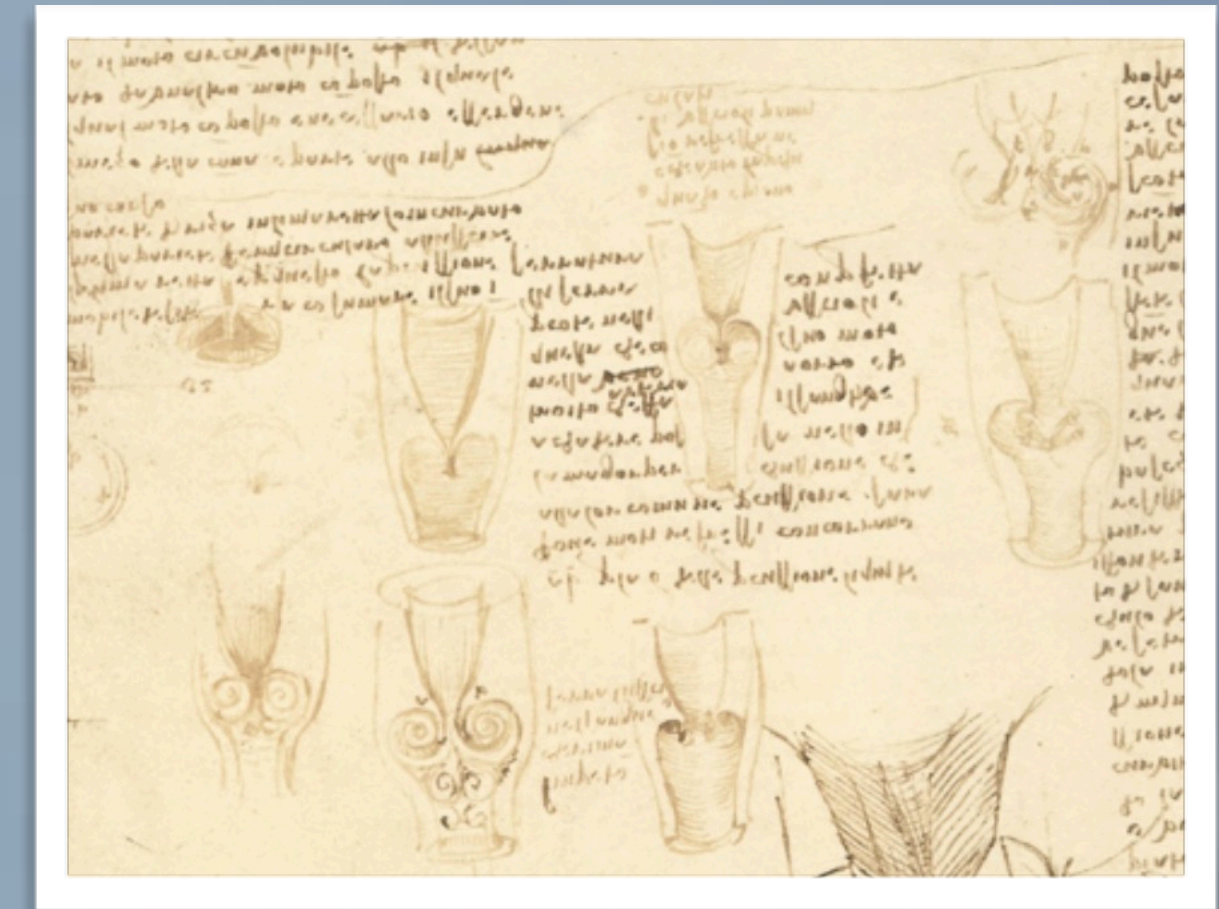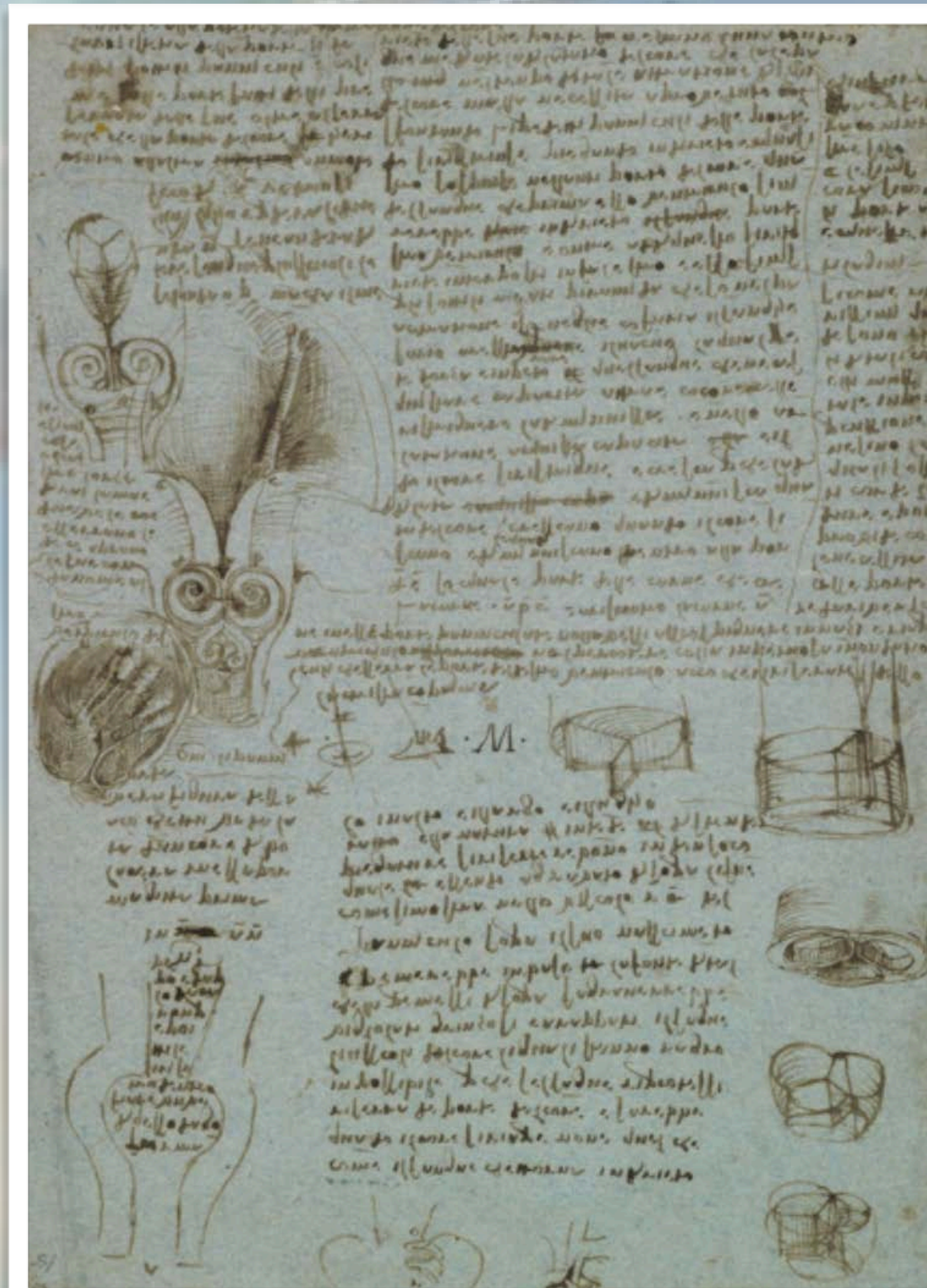Lt.Col. Fabrizio Palumbo

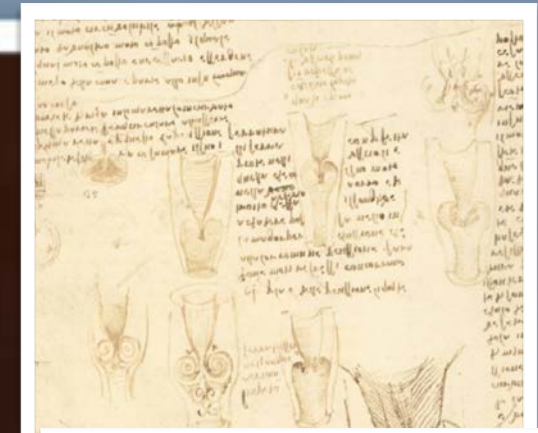
fabrizio.palumbo@aeronautica.difesa.it

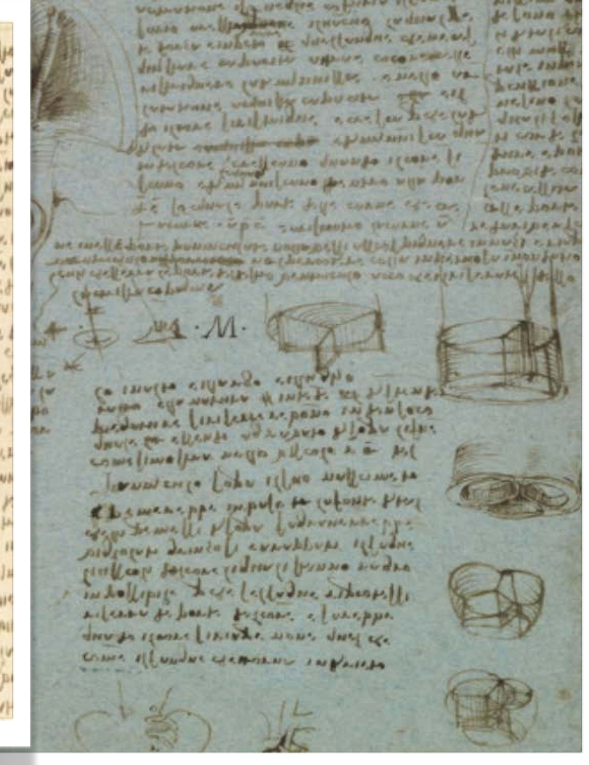

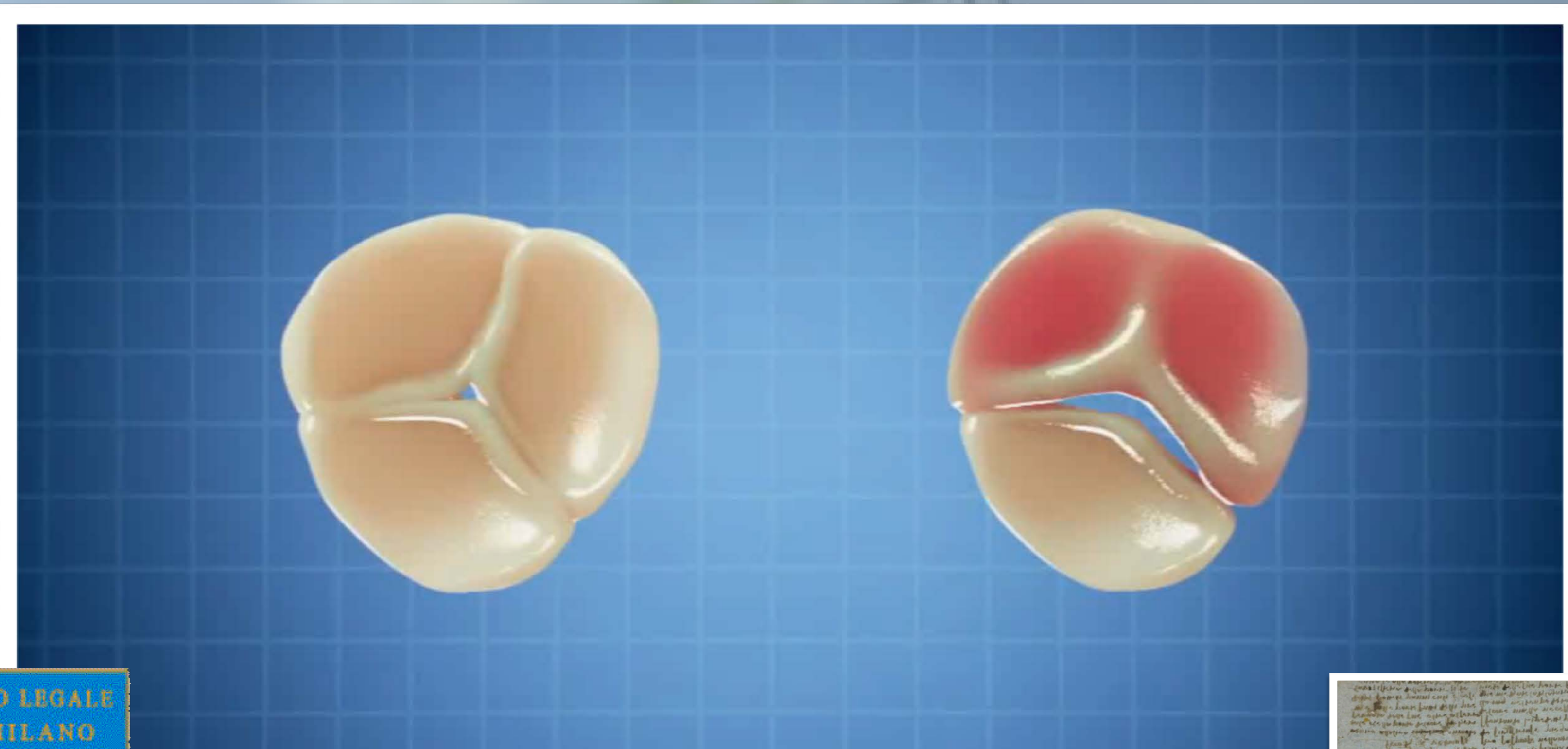
fabriziopalumbo@libero.it

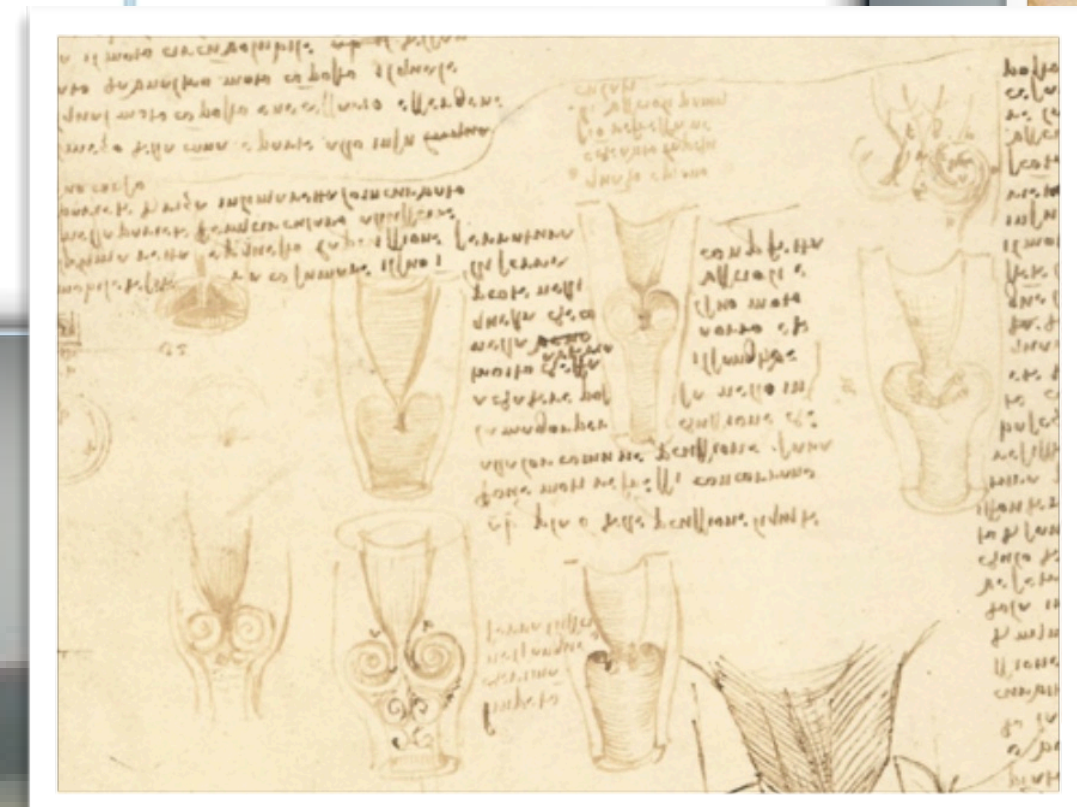
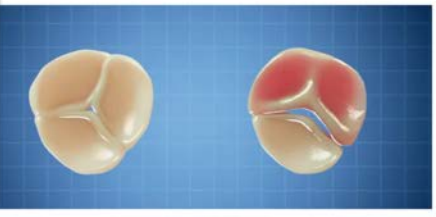
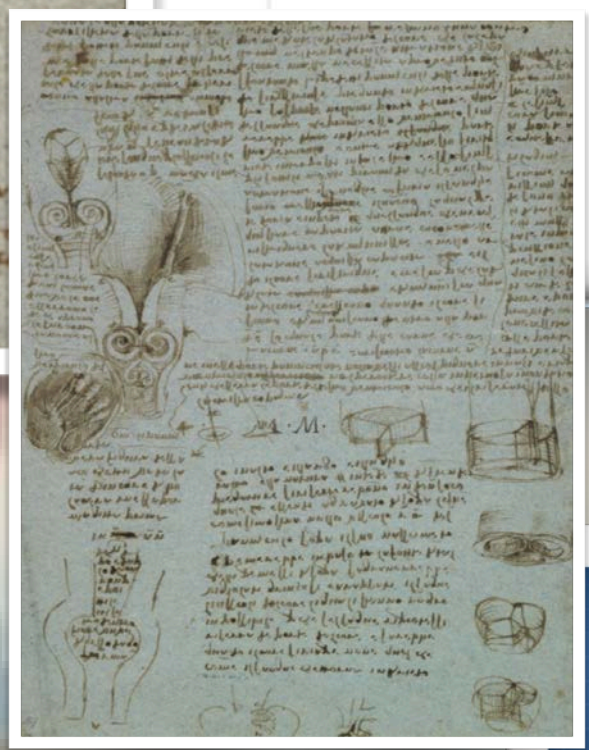
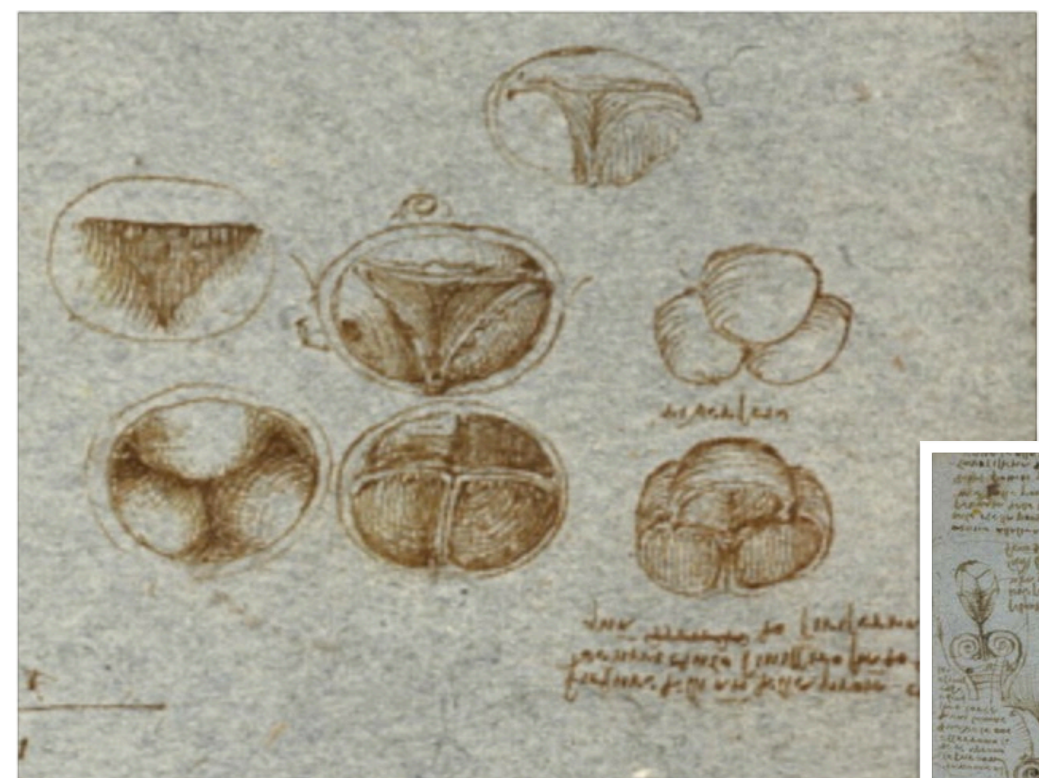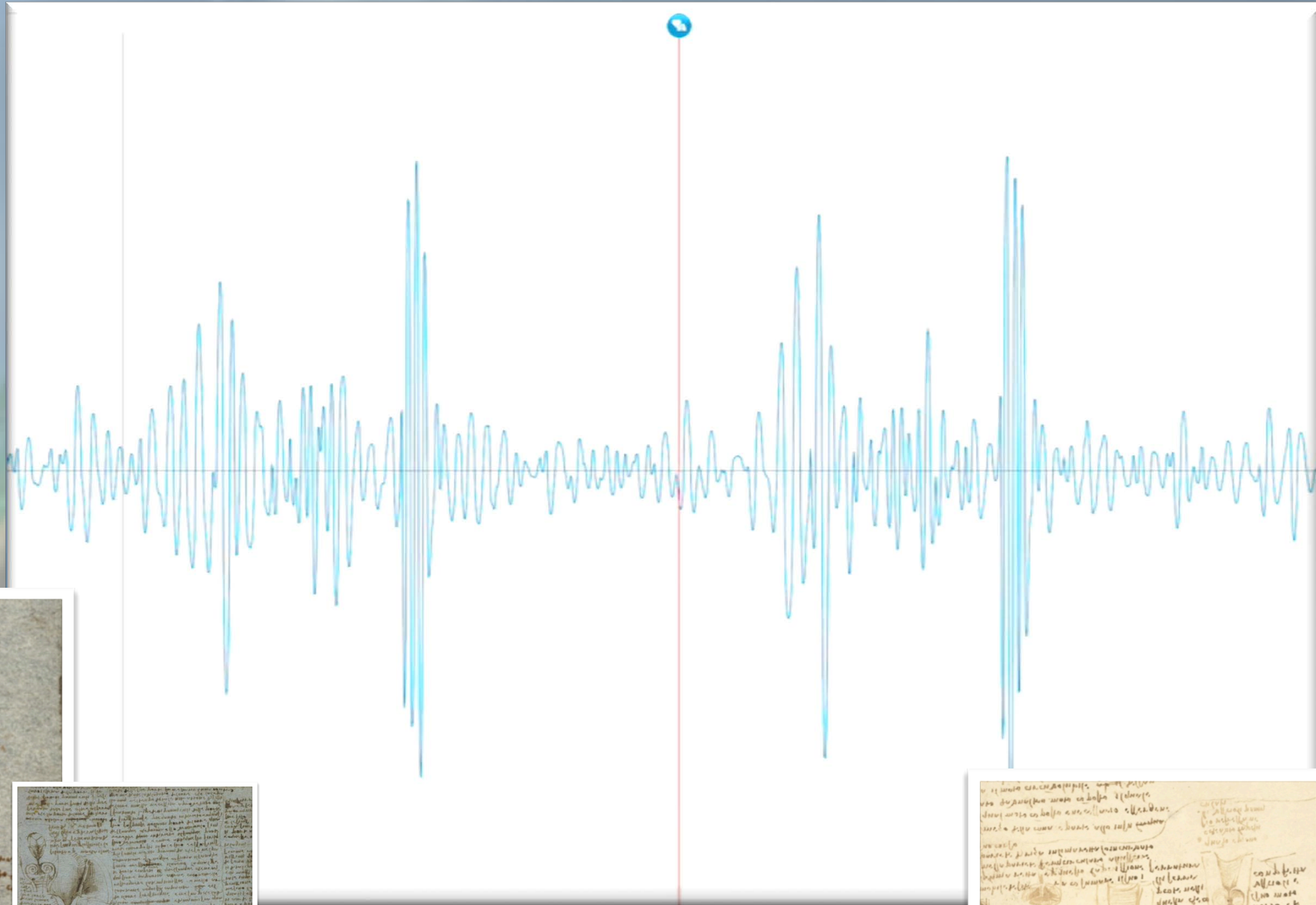



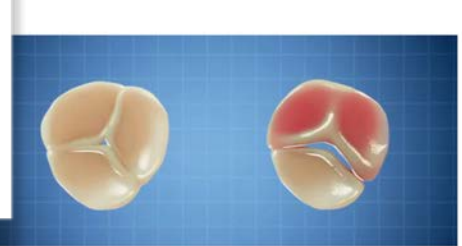
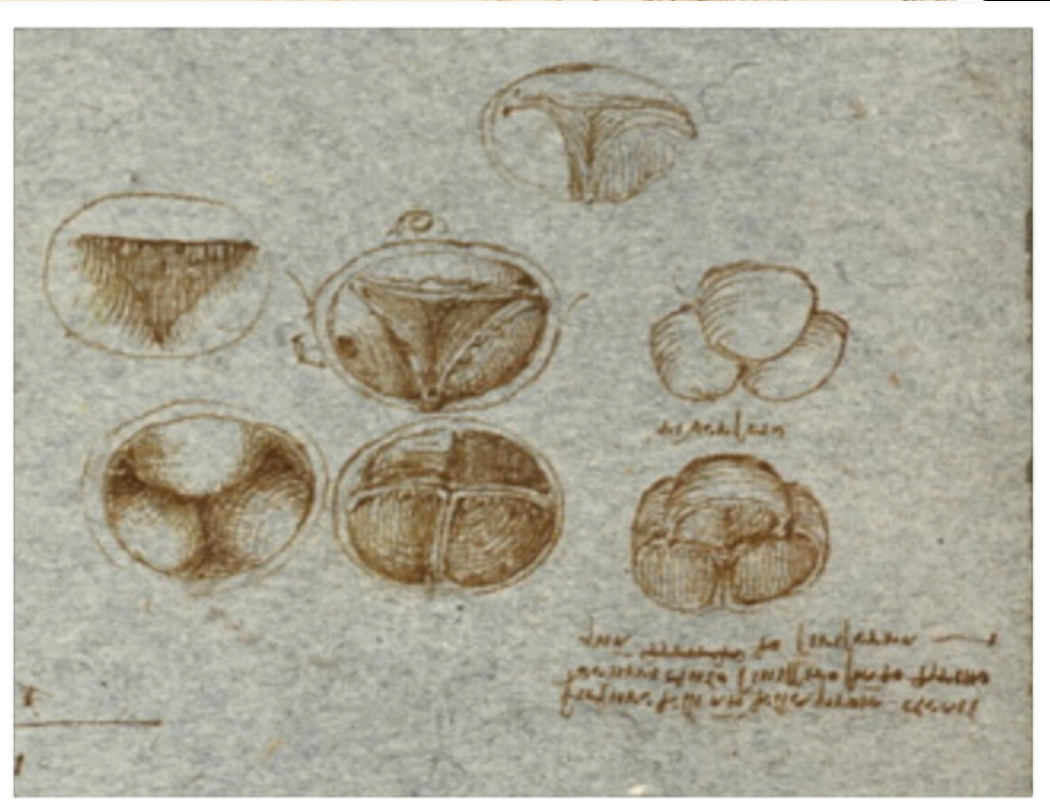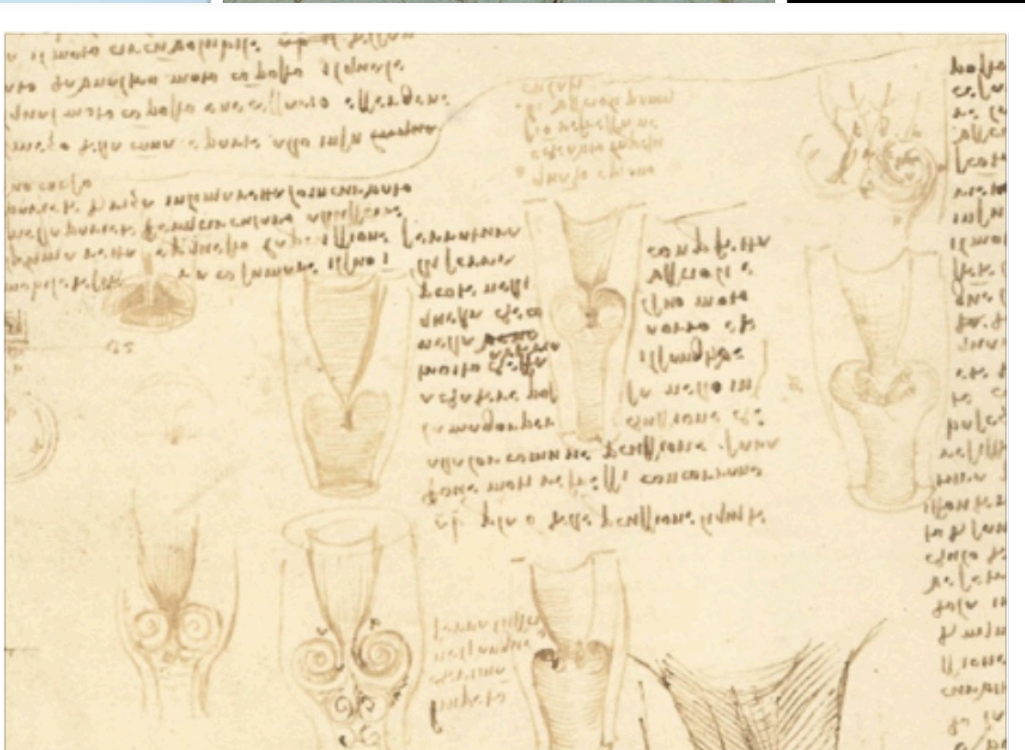

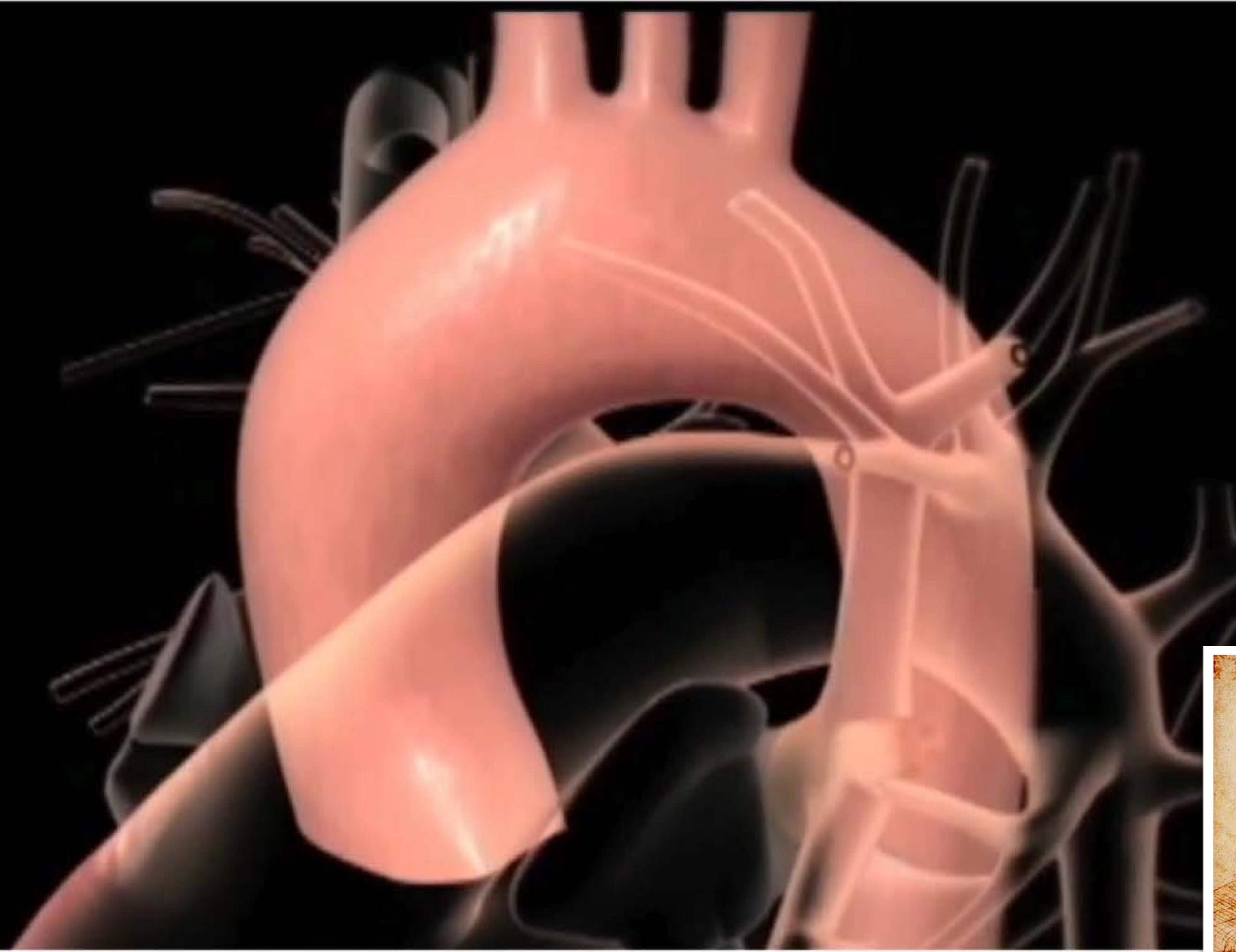
Leonardo Da Vinci (1452-1519)











Stenosis (37%)

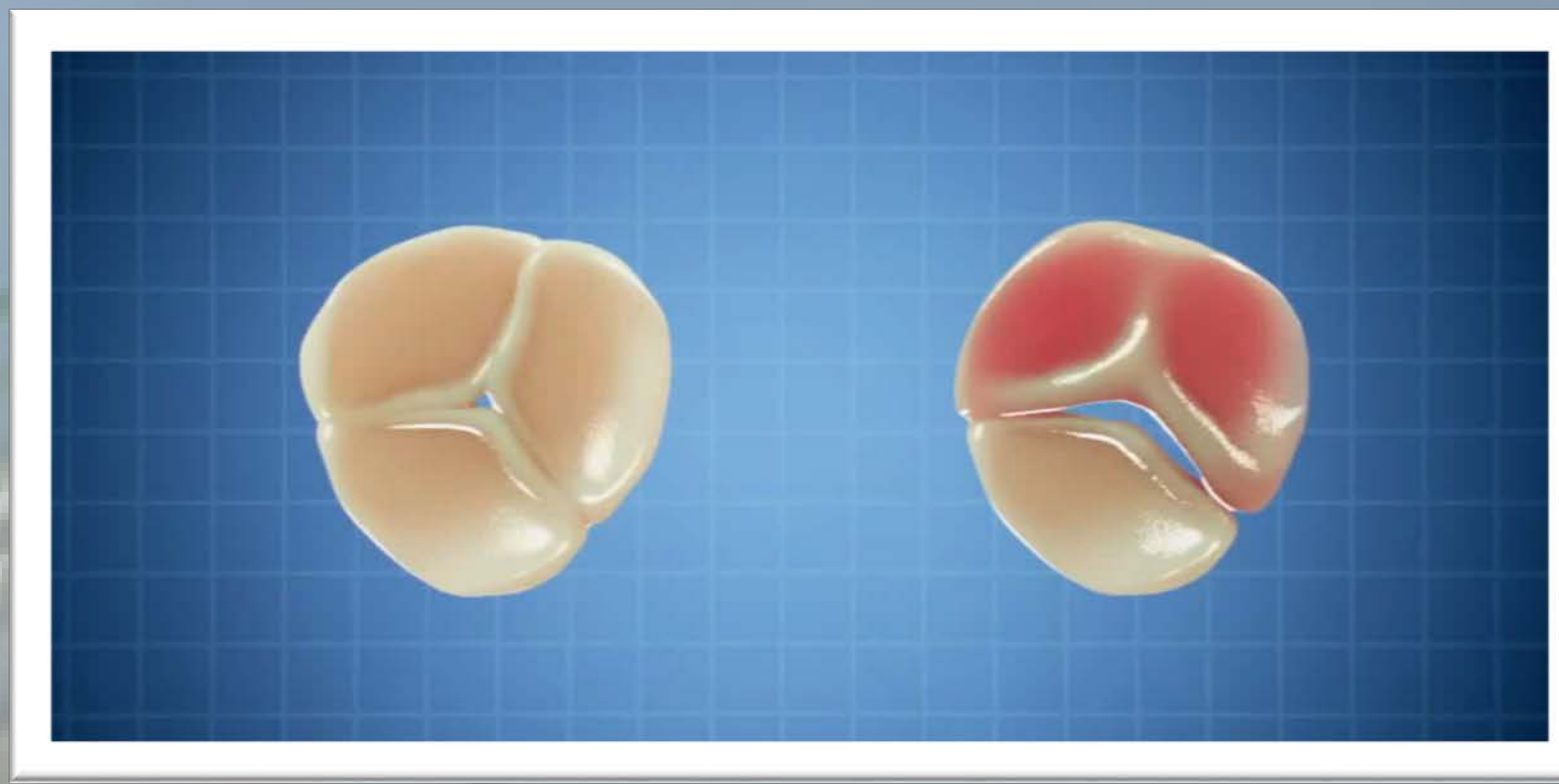
Regurgitation (20%)

Infection (2%)

Dilatation (74-91%)

Dissection (0,03-1%)

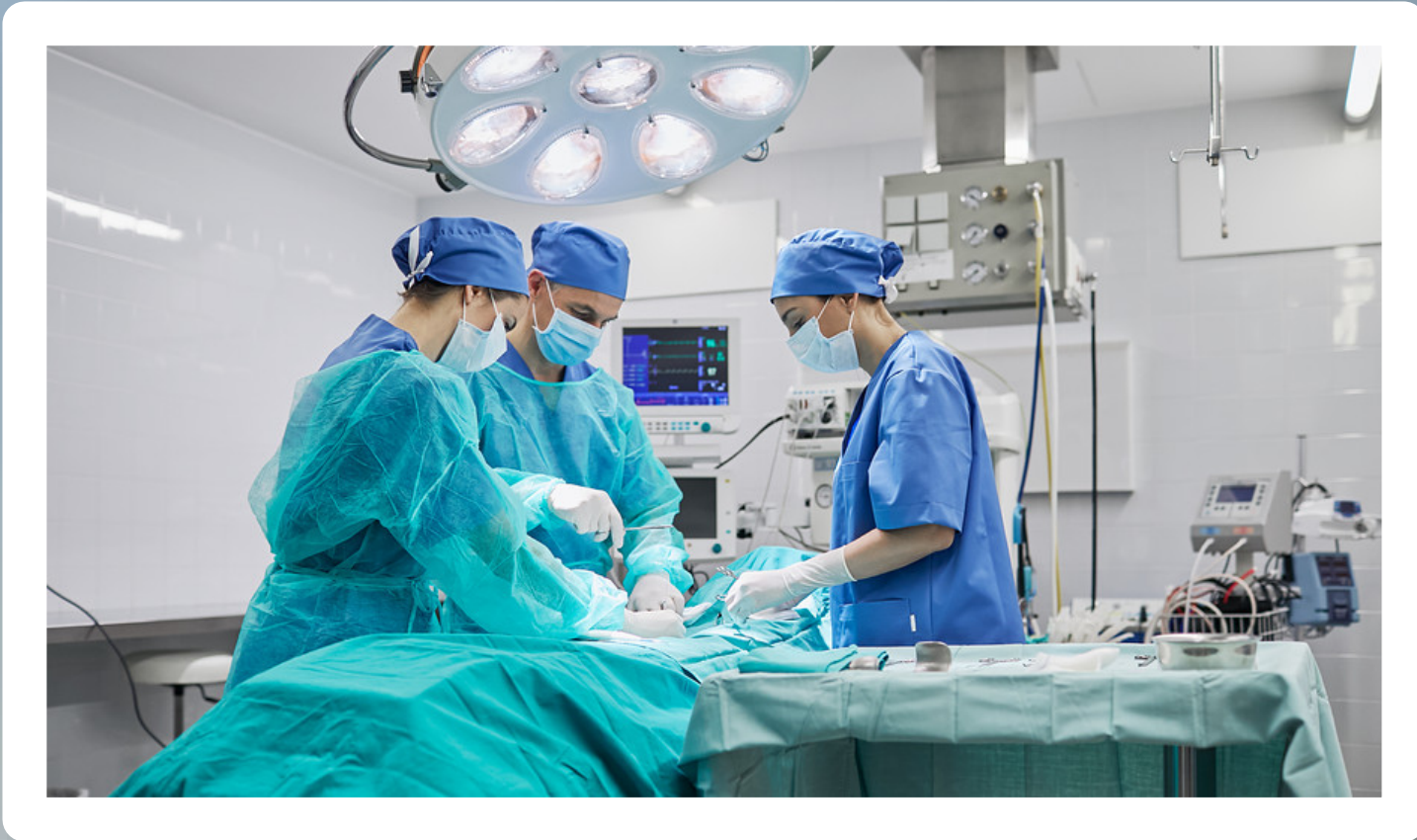Coartation (50% COA has BAV)



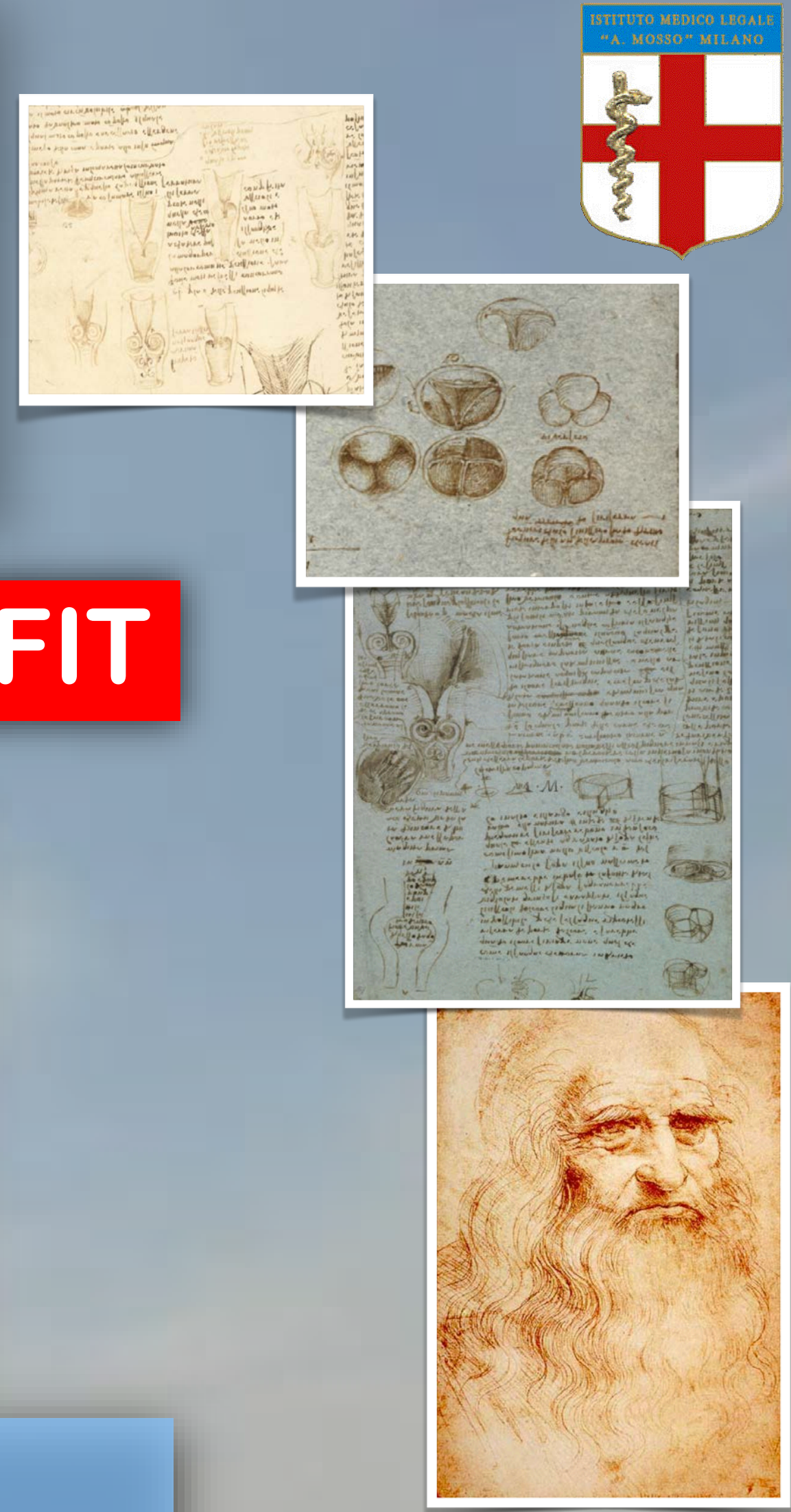FIT

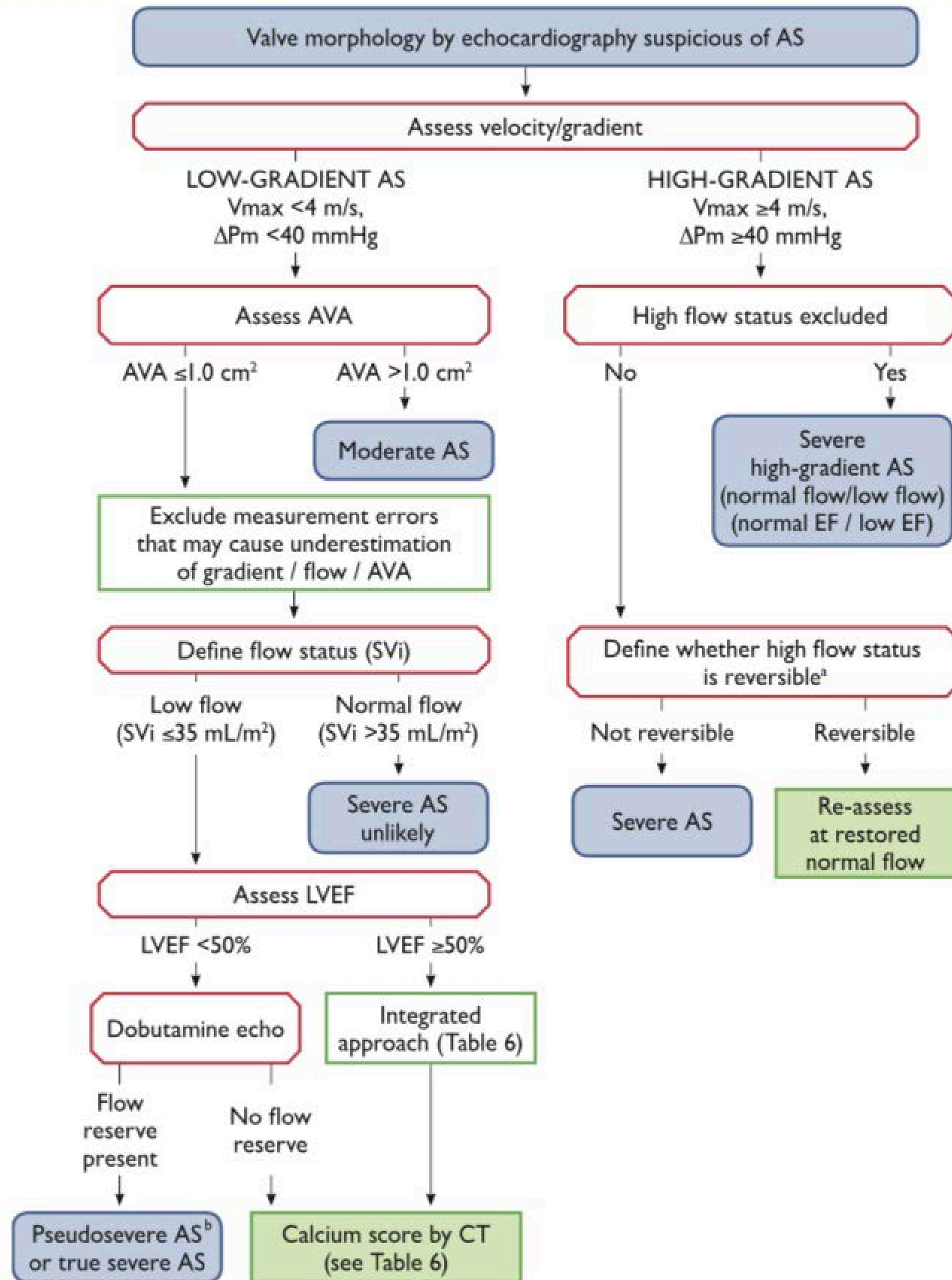
MULTI PILOT

NOT FIT



Surgery (21% for valve, 7% for aneurysm)





©ESC 2017



European Heart Journal (2017) 38, 2739–2786
doi:10.1093/eurheartj/ehx391

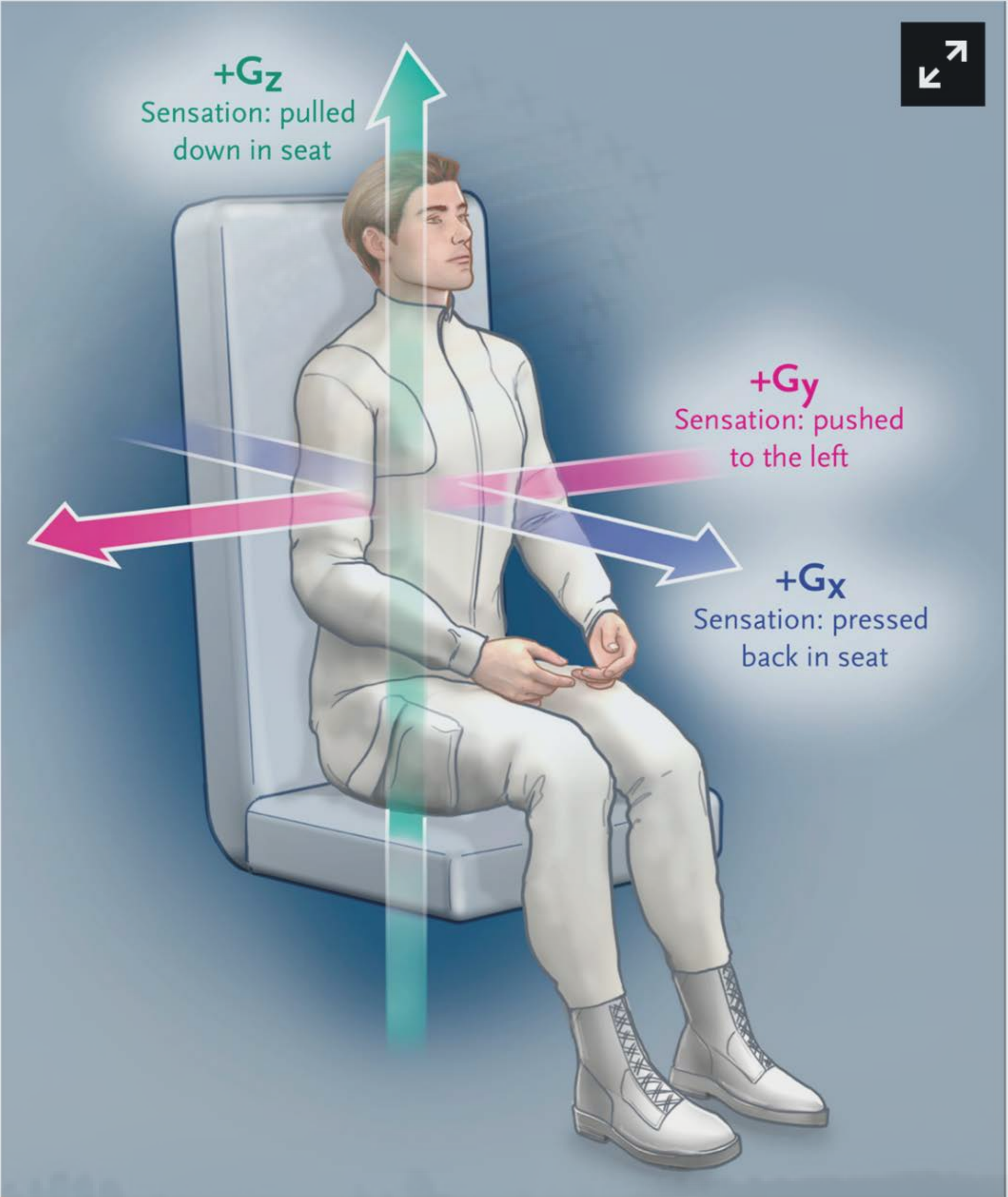
ESC/EACTS GUIDELINES

2017 ESC/EACTS Guidelines for the management of valvular heart disease

The Task Force for the Management of Valvular Heart Disease of the European Society of Cardiology (ESC) and the European Association for Cardio-Thoracic Surgery (EACTS)

Aortic Stenosis

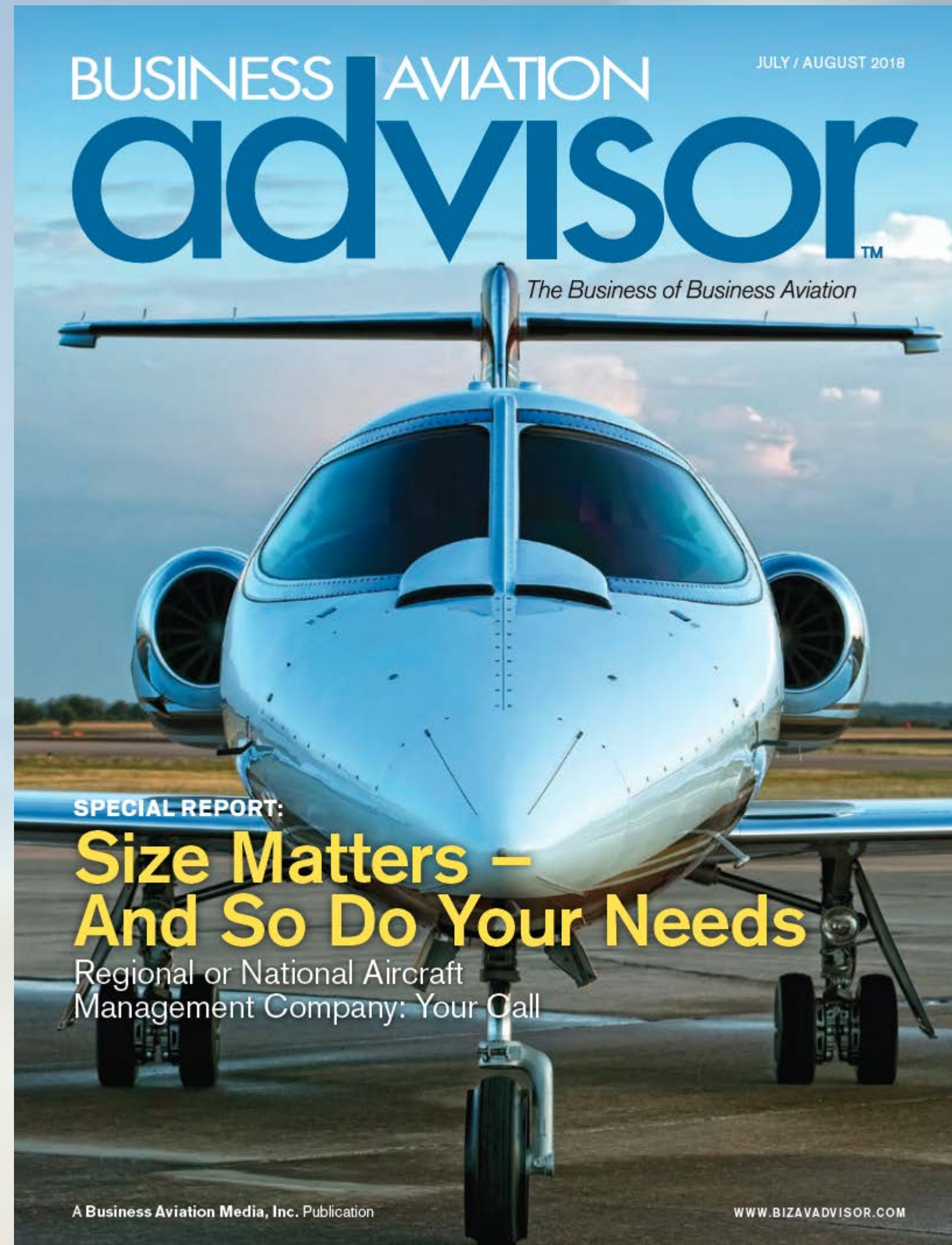MILD	MODERATE	SEVERE
• Mean ΔP • <20mmHg	• Mean ΔP • 20-39mmHg	• Mean ΔP • ≥40mmHg
FIT	MULTI PILOT	NOT FIT



- **Congenital heart disease:**
- **Incidence on 1 million live births (USA)**

- IVD
- Botallo
- IAD
- AVdefect
- Sten POLM
- Sten AO
- Coart AO
- Fallot
- TGV compl
- ipoplasia Right Ventr
- atresia tricusp
- Anom Ebstein
- Atresia Polm
- ipoplasia Left ven
- trunc Arter
- Right V double ex
- uniVentr
- abnormal polm ven conn
- Bicuspid Aorta





Surgery?

- Severe Valvular Stenosis/Regurgitation
- **Aortic Root Dilatation**
- **>45mm** (severe valve dysfunction) ESC/AHA
- **>50mm** (familiarity, symptoms) ESC/AHA
- **>55mm** (valve ok)
- Risk dissection >50mm

(Circulation. 2014;129:2691-2704.)



Military Pilot #1

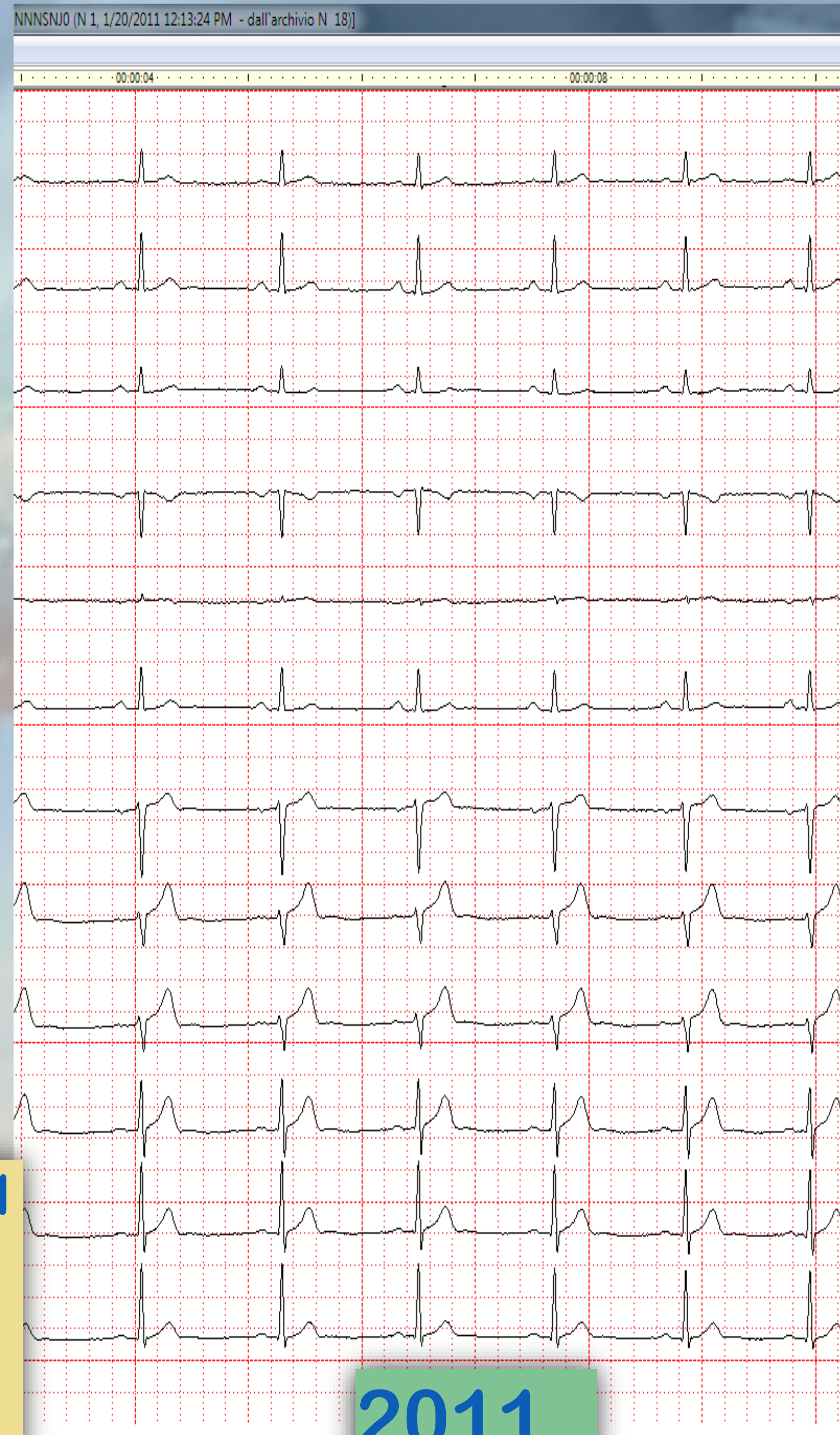
RF104G



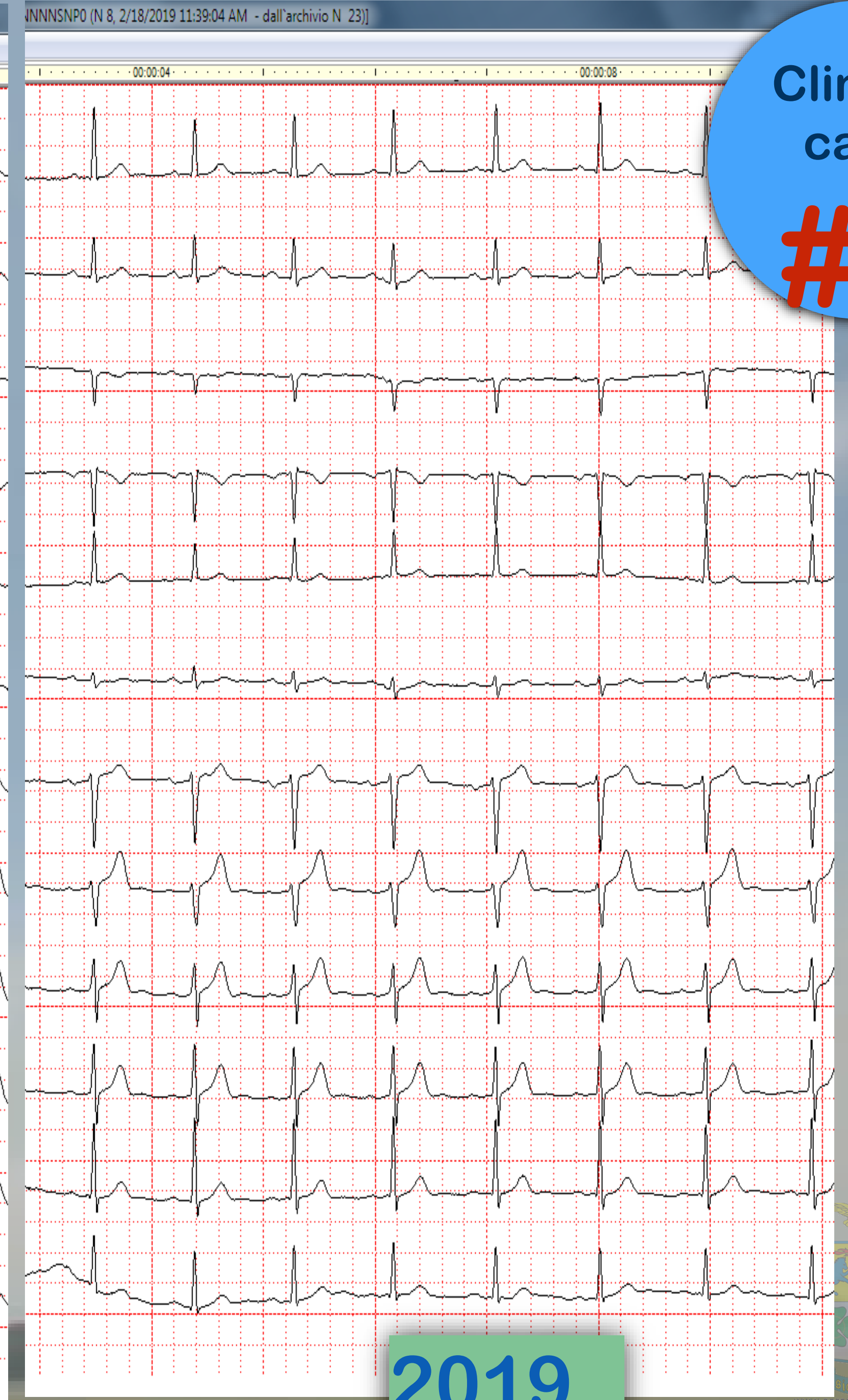
- symptomless
- silent anamnesis
- male sex
- born 1958
- no therapy

- BP=130/90
- HR=55/min
- BMI=26,3

- right systolic murmur 2/6 2001
- no Aortic regurgitation
- aortic velocity 1.1 m/sec
- Mean $\Delta P < 10$ mmHg




2011



2019

Clinical case

#1



Military Pilot #1

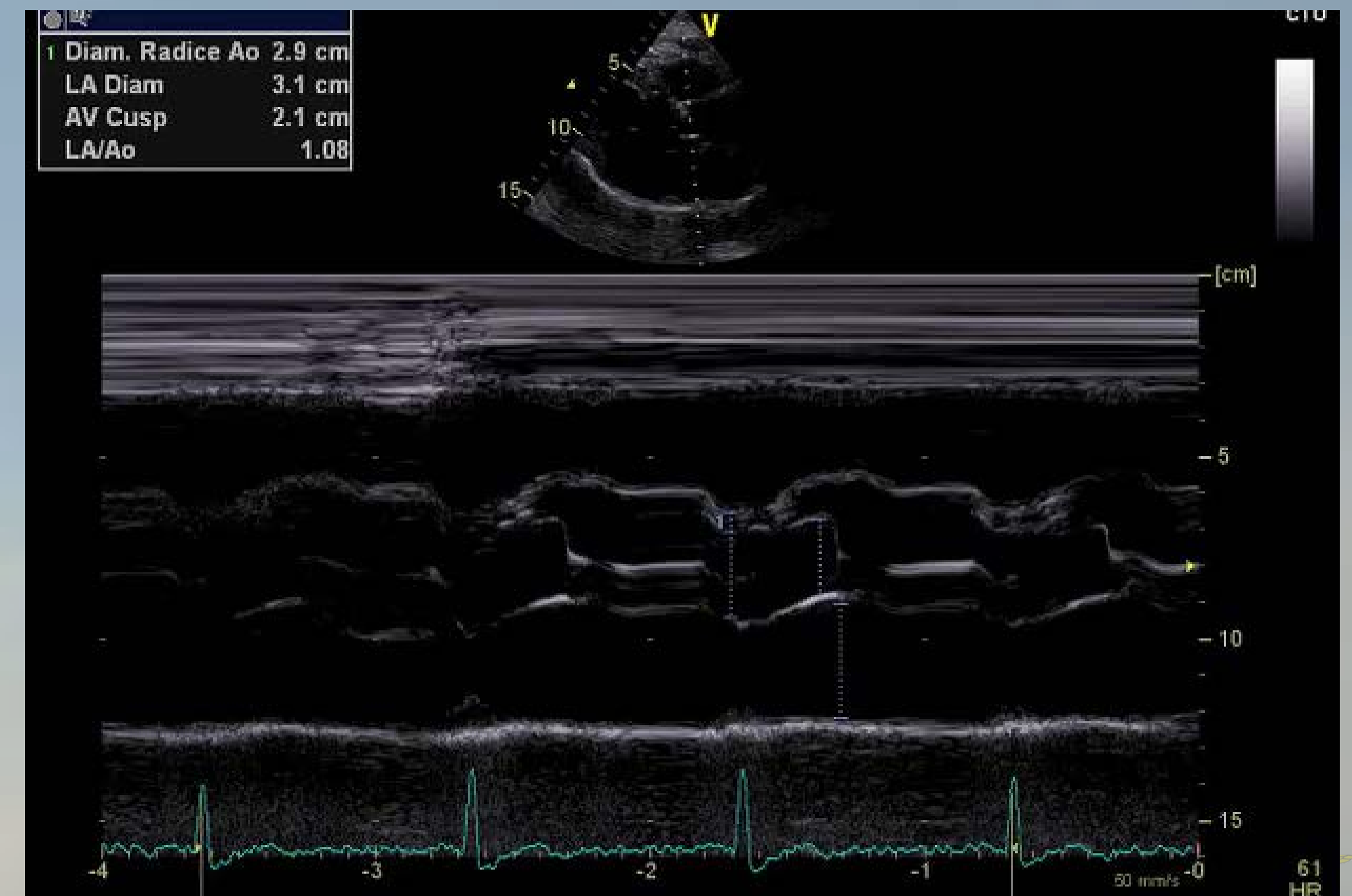
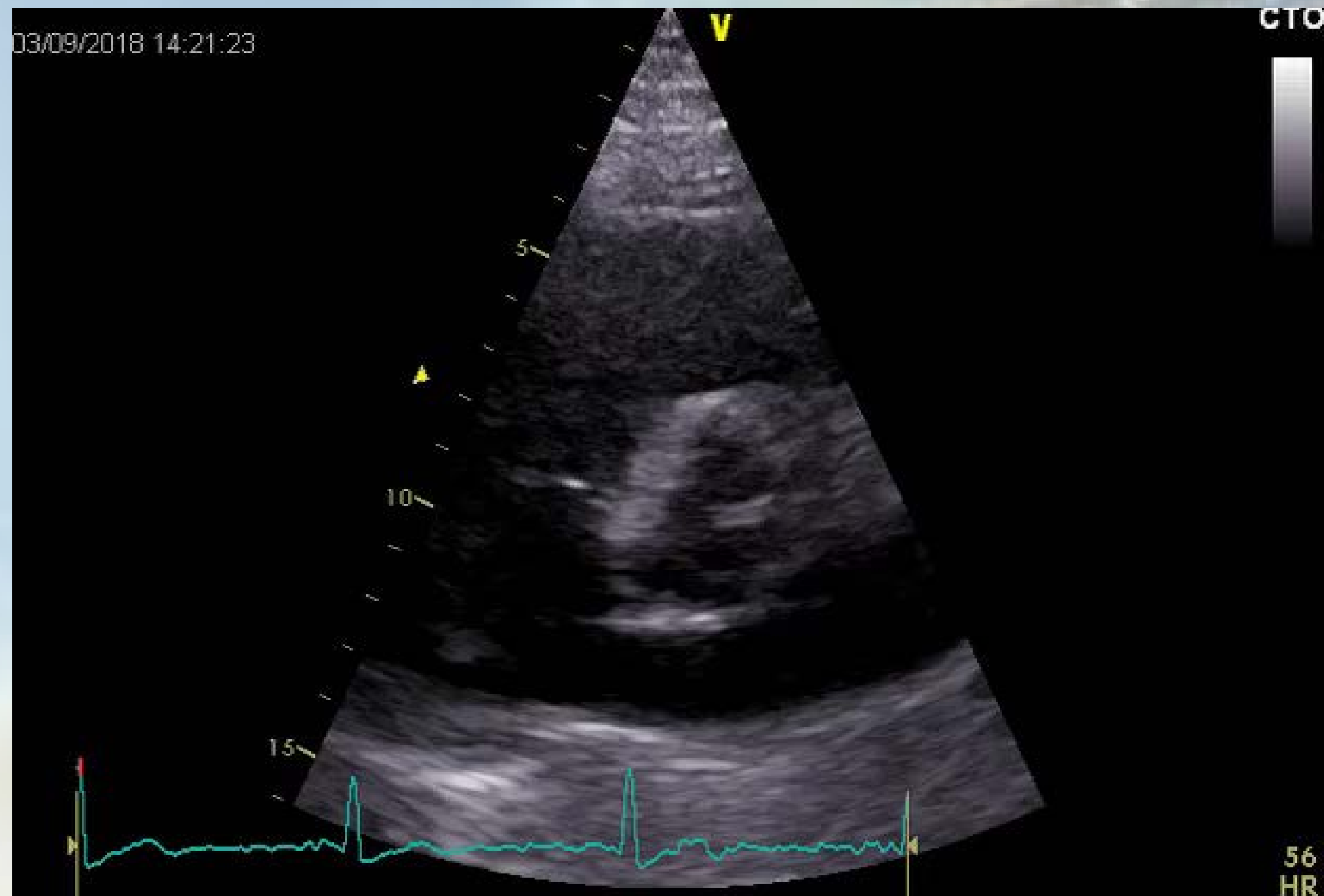
RF104G



- symptomless
- silent anamnesis
- male sex
- born 1958
- no therapy

Clinical case

#1



- BP=130/90
- HR=55/min
- BMI=26,3

- right systolic murmur 2/6 2001
- no Aortic regurgitation
- aortic velocity 1.1 m/sec
- Mean $\Delta P < 10$ mmHg

Military Pilot #1

RF104G

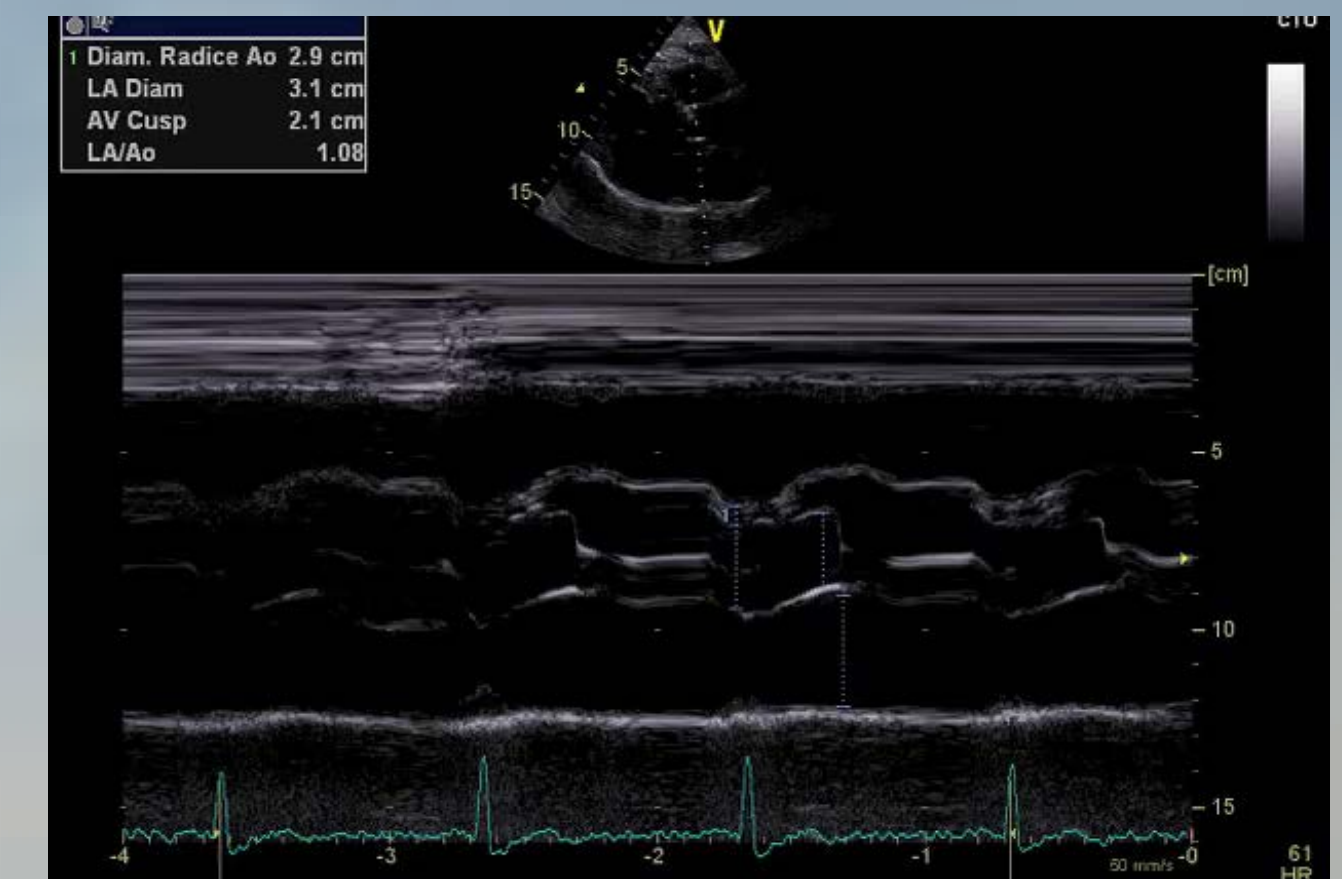
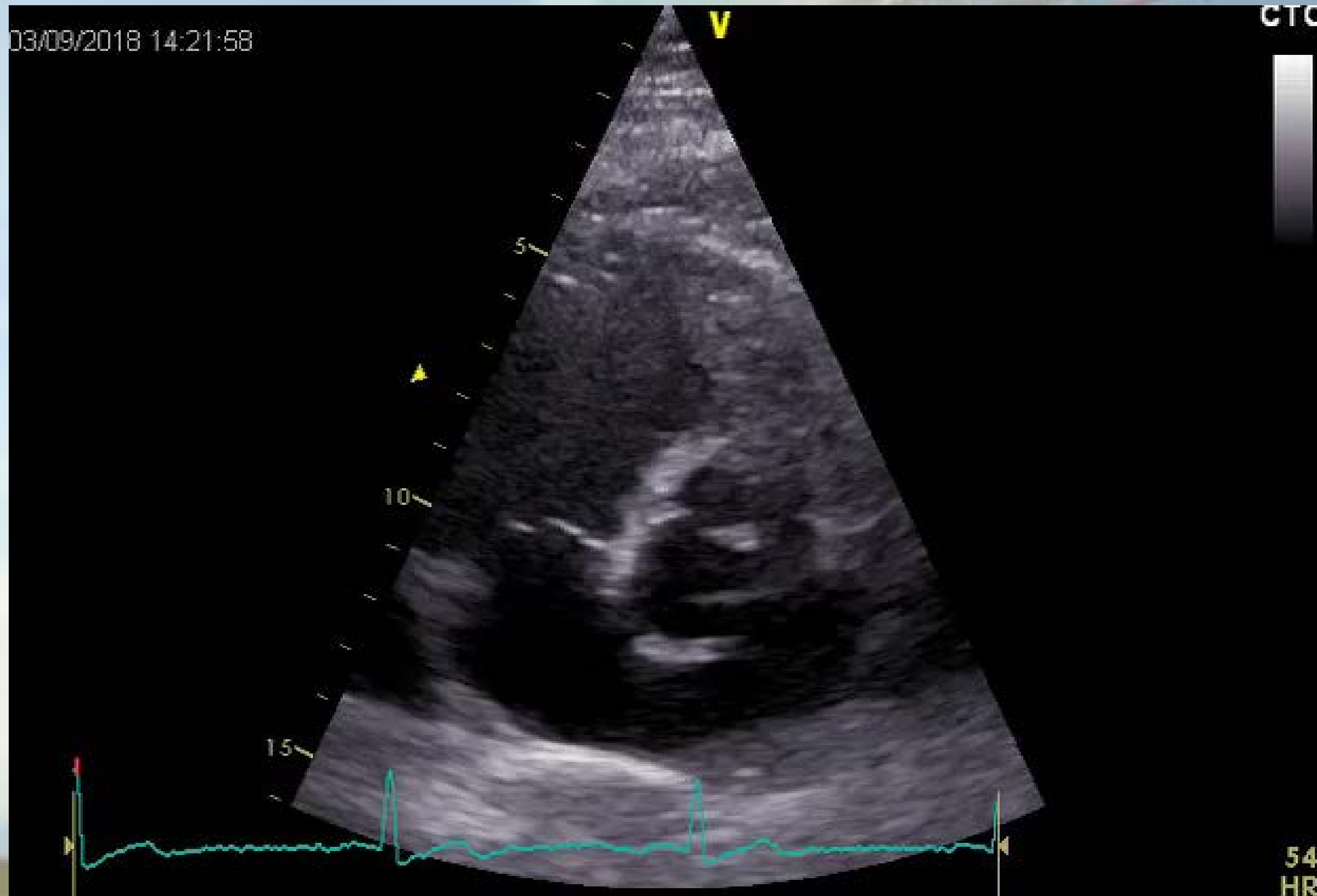


- symptomless
- silent anamnesis
- male sex
- born 1958
- no therapy

Clinical case

#1

- BP=130/90
- HR=55/min
- BMI=26,3



- right systolic murmur 2/6 2001
- no Aortic regurgitation
- aortic velocity 1.1 m/sec
- Mean $\Delta P < 10$ mmHg

Military Pilot #1

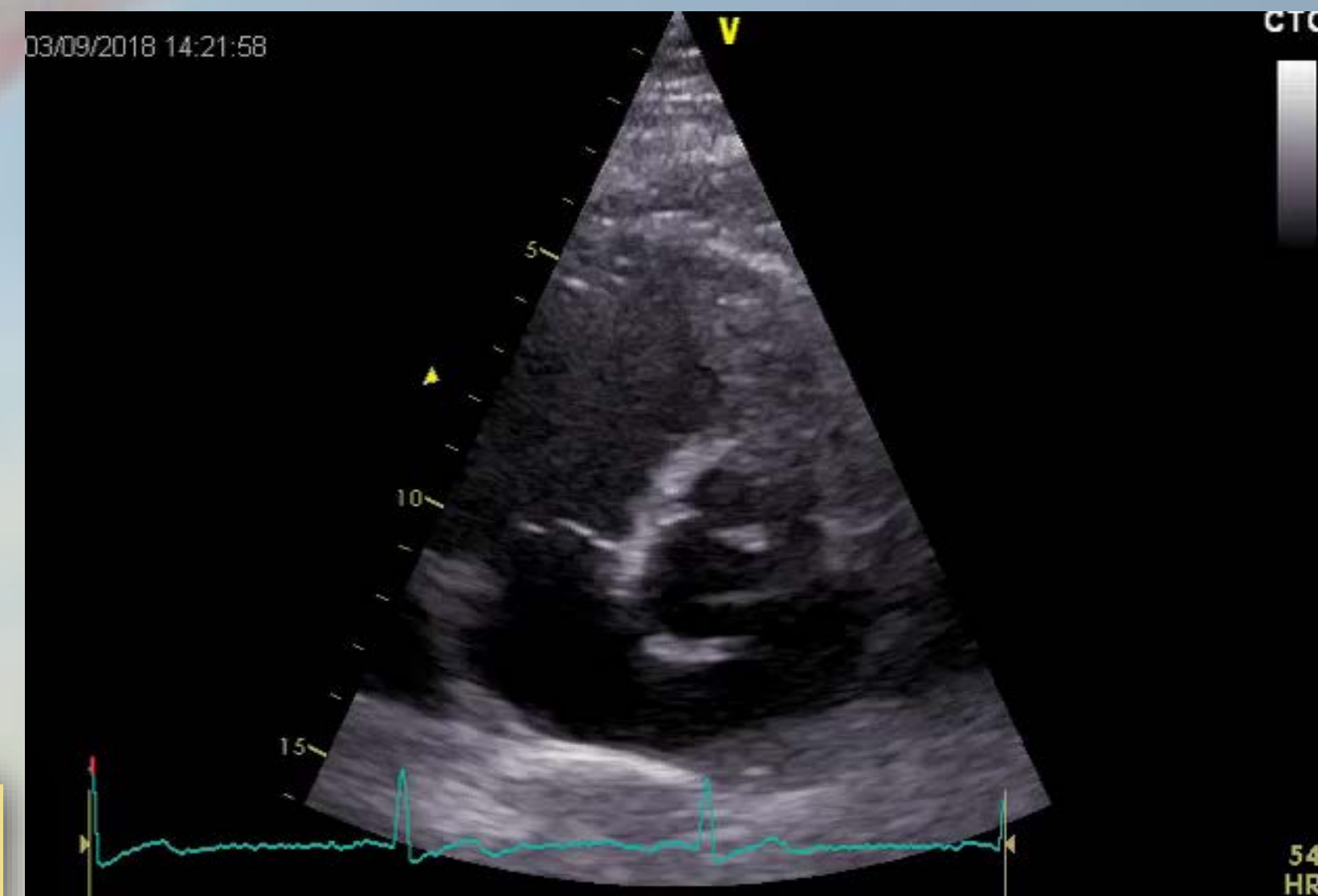
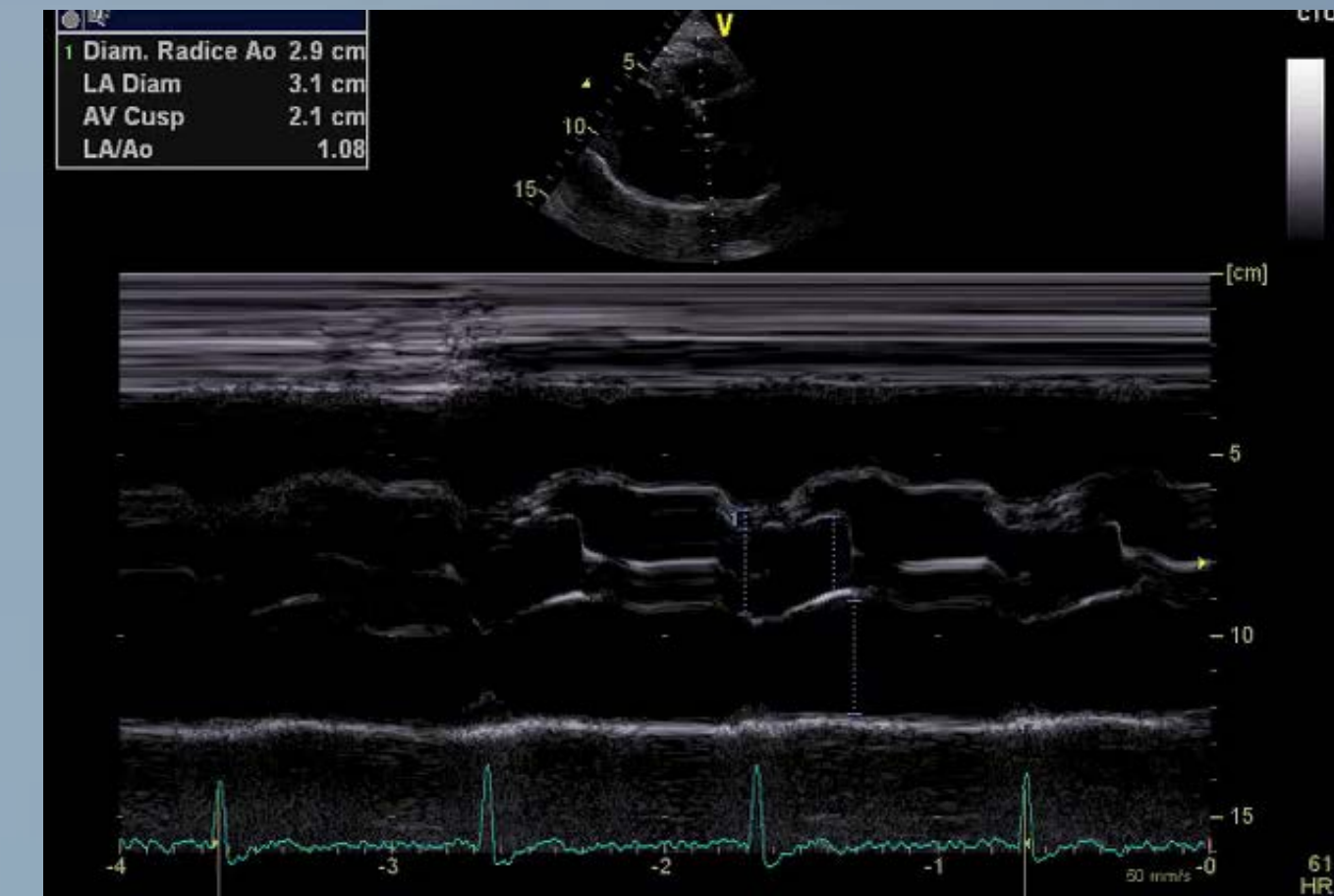
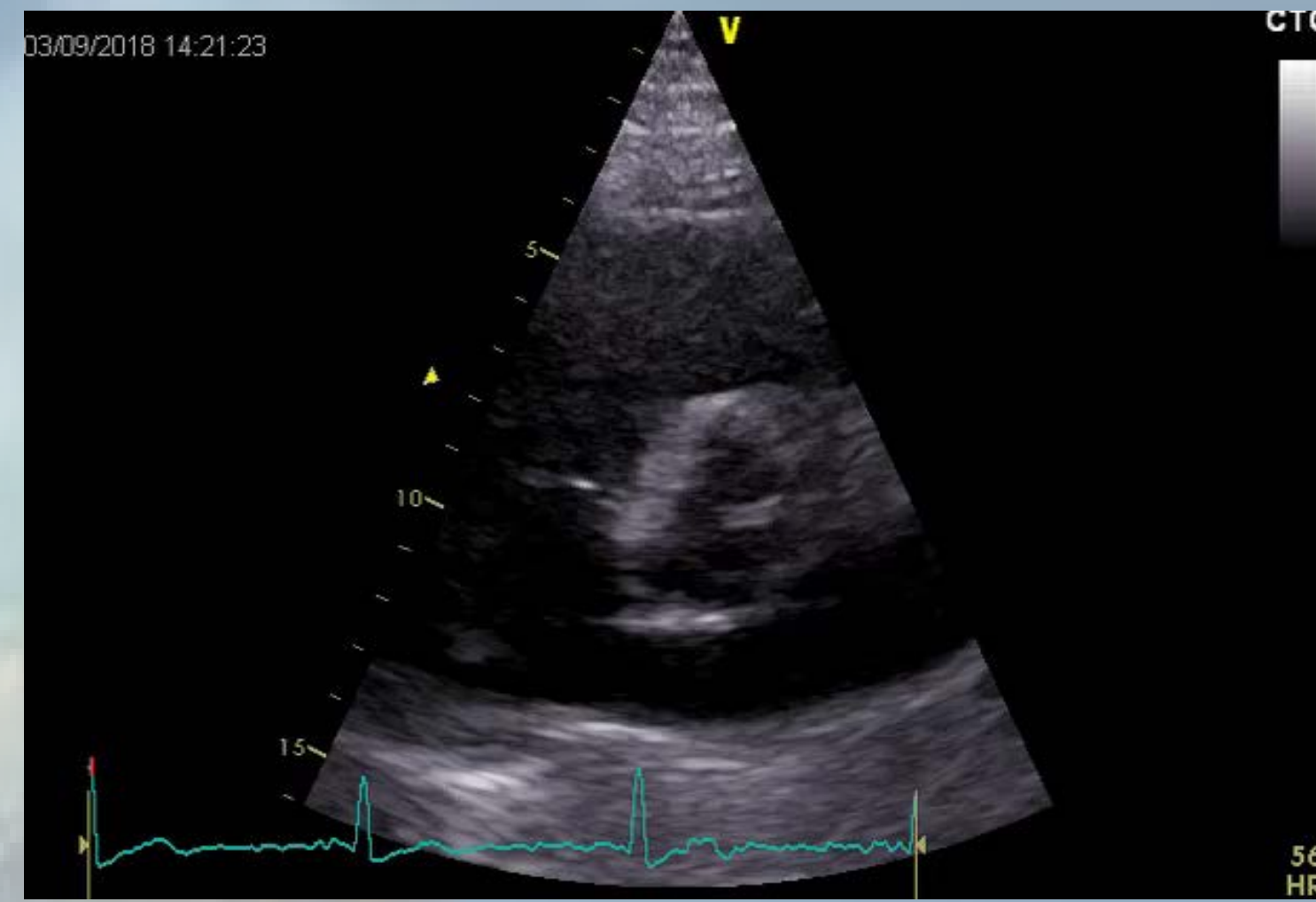
RF104G



- symptomless
- silent anamnesis
- male sex
- born 1958
- no therapy

- BP=130/90
- HR=55/min
- BMI=26,3

- right systolic murmur 2/6 2001
- no Aortic regurgitation
- aortic velocity 1.1 m/sec
- Mean $\Delta P < 10$ mmHg



Clinical case

#1

Single Pilot

Military Pilot #2

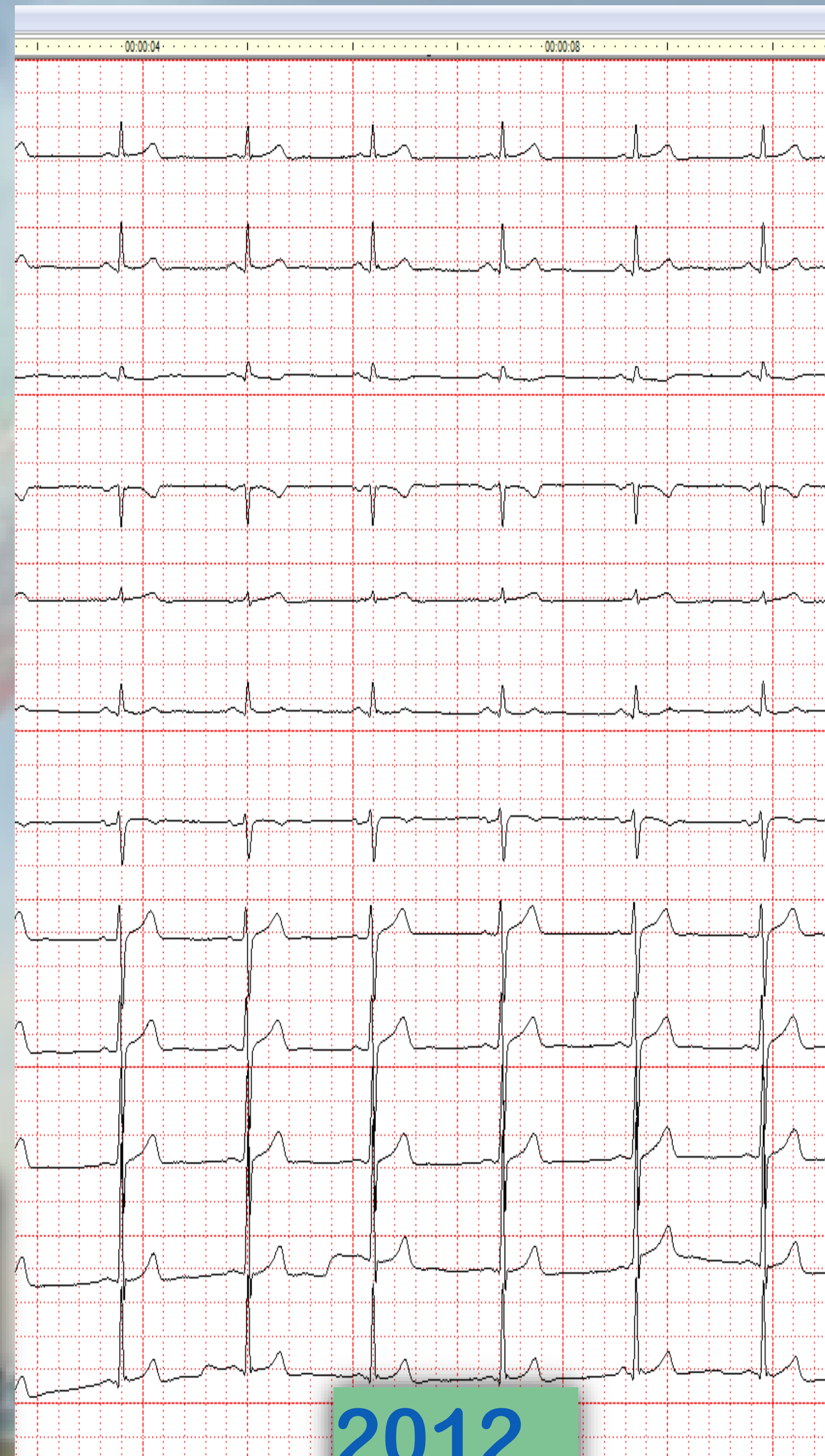
AMX Fighter



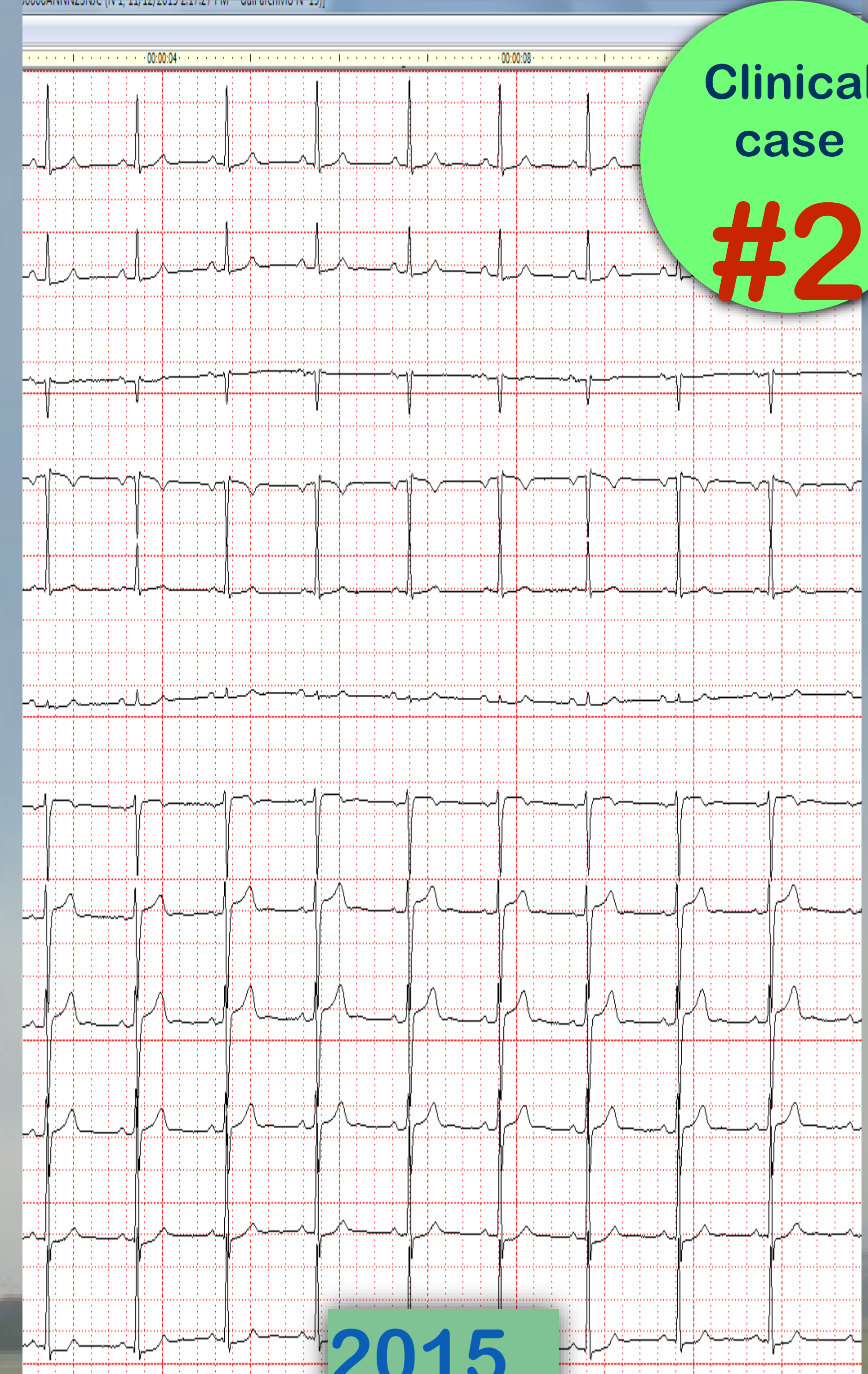
- symptomless
- silent anamnesis
- male sex
- born 1960
- ACE2 -2015

- BP=120/75
- HR=65/min
- BMI=23,1

- right systolic murmur 2/6 2001
- Aortic regurgitation 2010
- aortic velocity 1.9 m/sec
- Mean $\Delta P < 20$ mmHg



2012



2015

Clinical case

#2

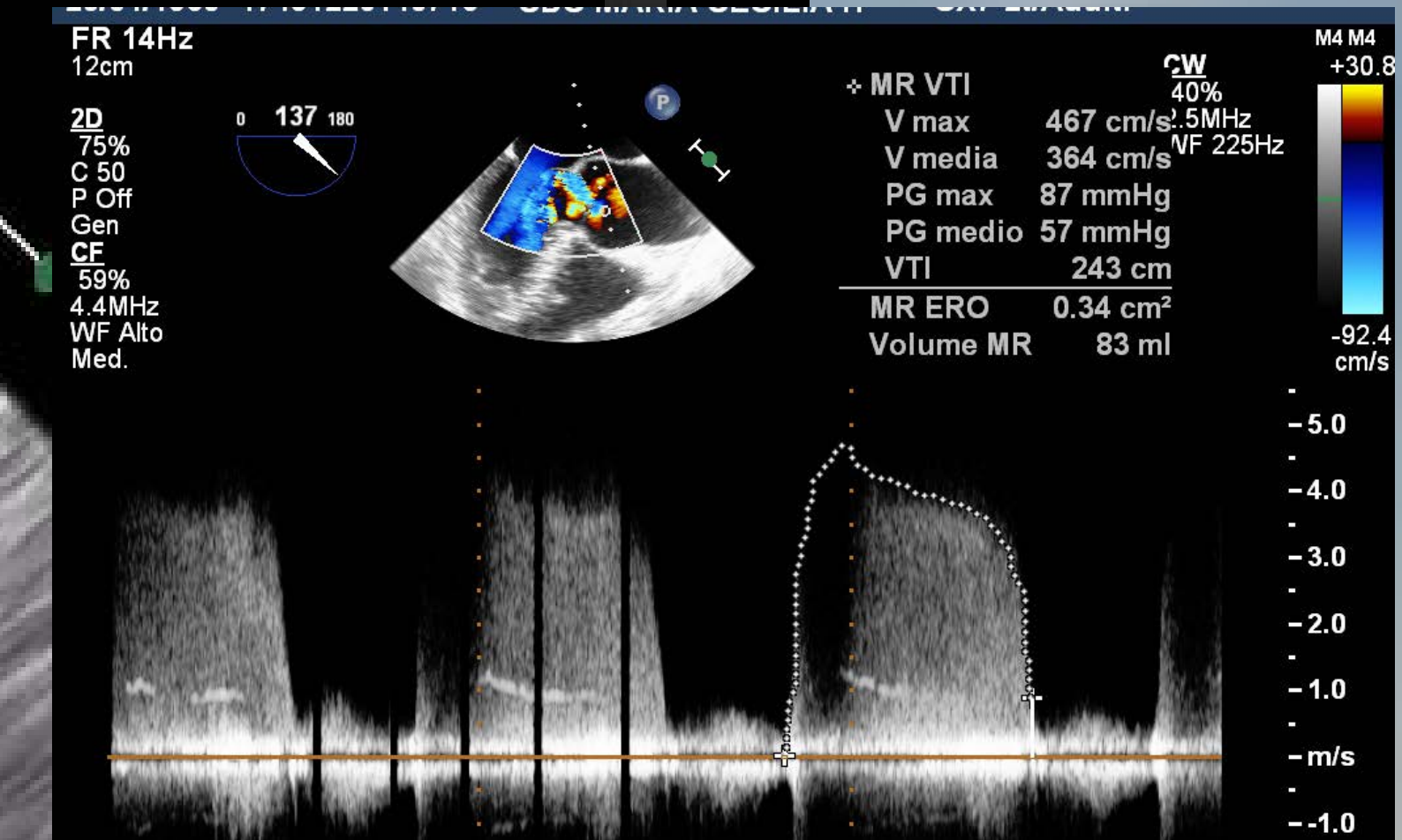
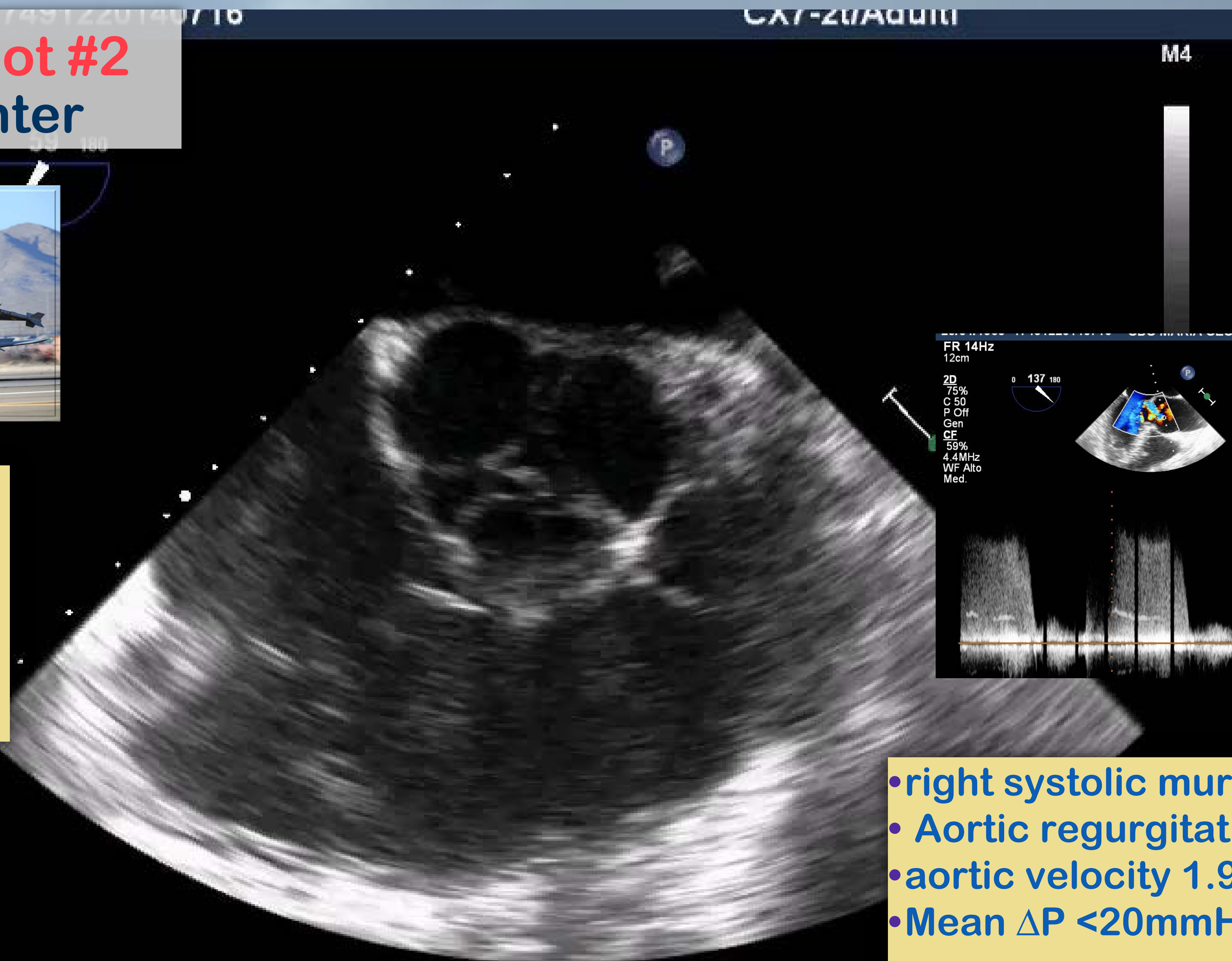
Military Pilot #2 AMX Fighter



- symptomless
- silent anamnesis
- male sex
- born 1960
- ACE2 -2015

- BP=120/75
- HR=65/min
- BMI=23,1

Temp. PAZ.: 37.0C
Temp. TEE: 38.6C



- right systolic murmur 2/6 2001
- Aortic regurgitation 2010
- aortic velocity 1.9 m/sec
- Mean $\Delta P < 20$ mmHg

63 bpm

Clinical case
#2

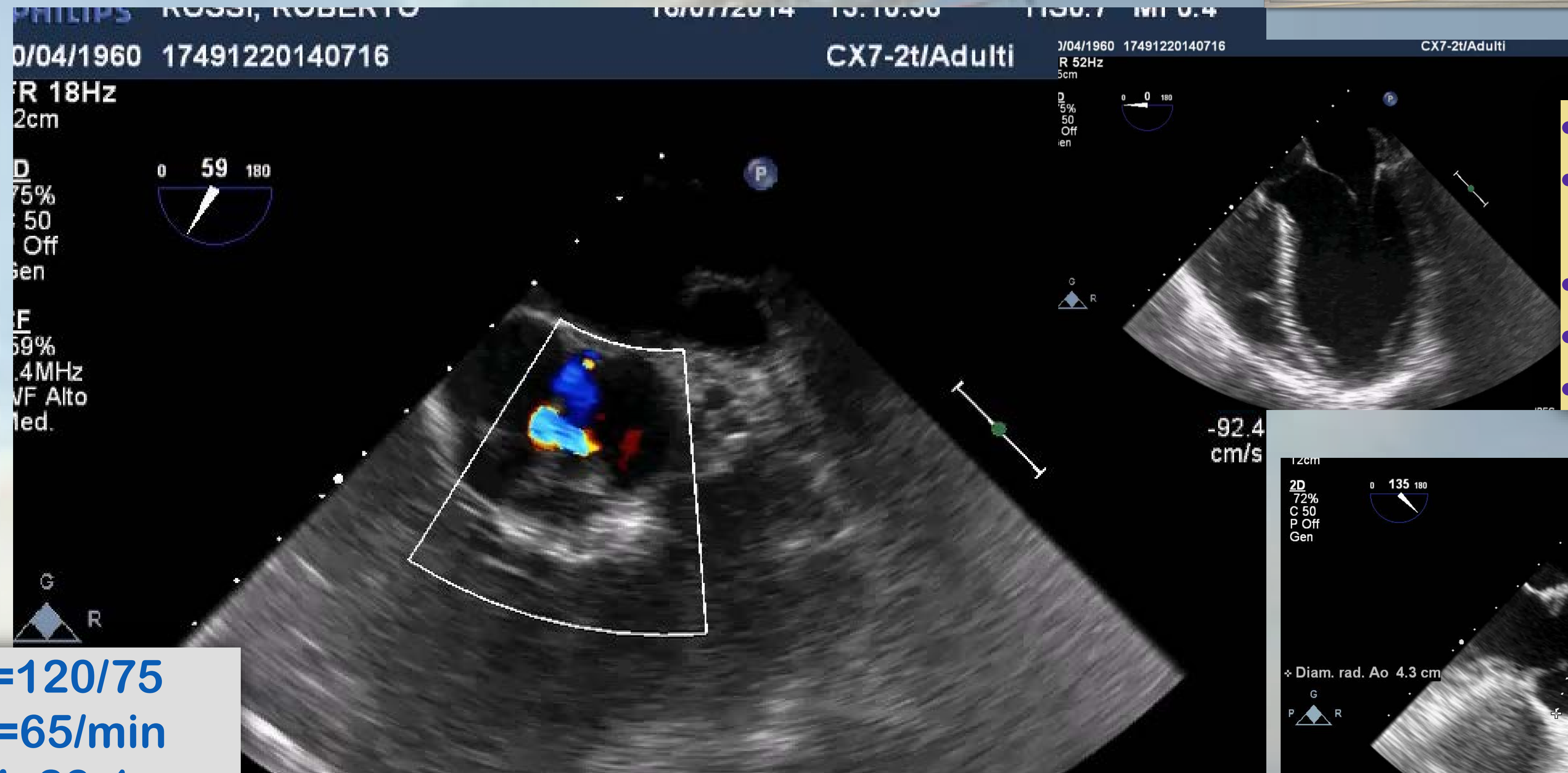Military Pilot #2 AMX Fighter

- right systolic murmur 2/6 2001
- Aortic regurgitation 2010
- aortic velocity 1.9 m/sec
- Mean $\Delta P < 20 \text{ mmHg}$



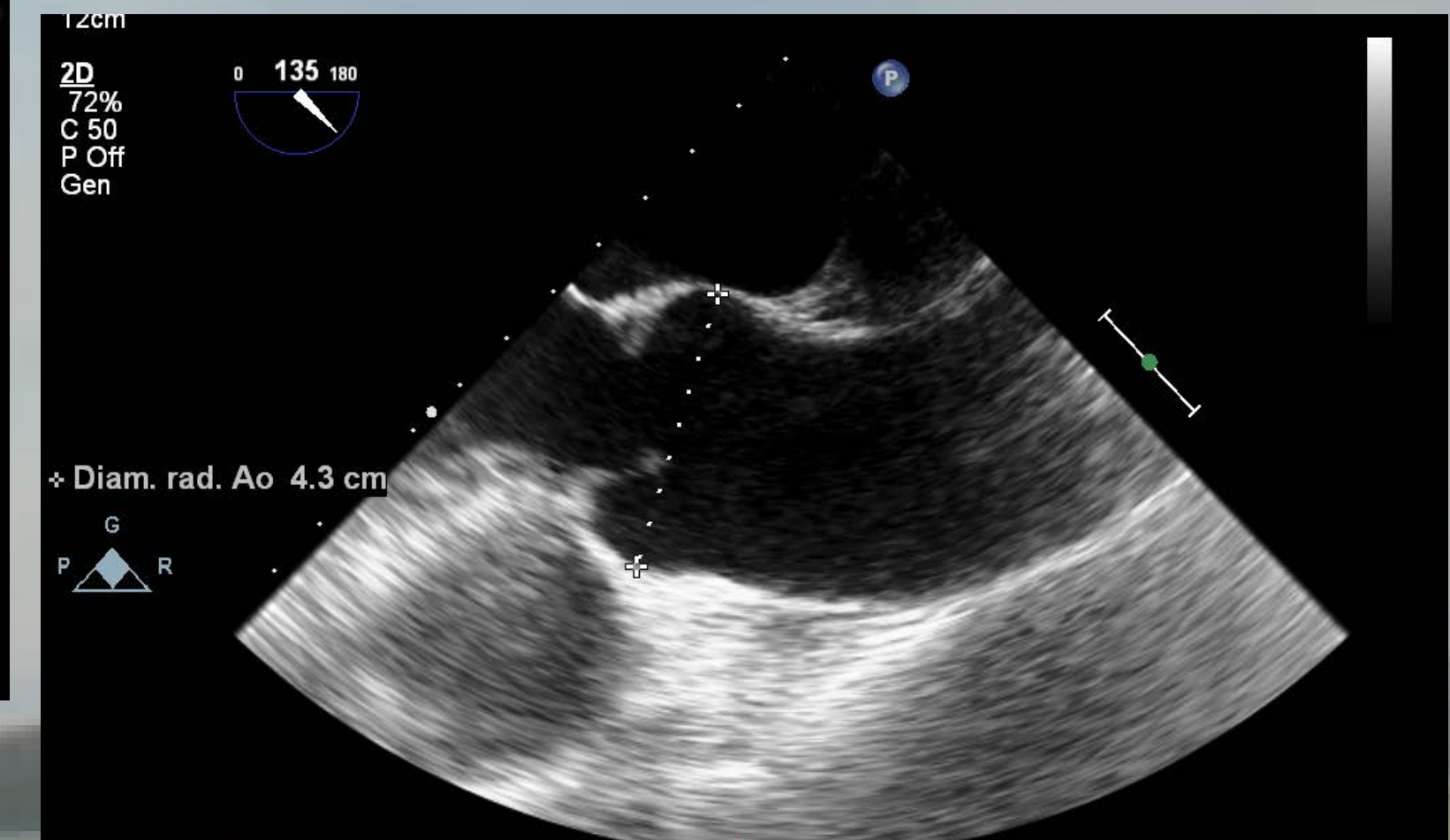
Clinical
case

#2



- symptomless
- silent anamnesis
- male sex
- born 1960
- ACE2 -2015

- BP=120/75
- HR=65/min
- BMI=23,1



Military Pilot #2

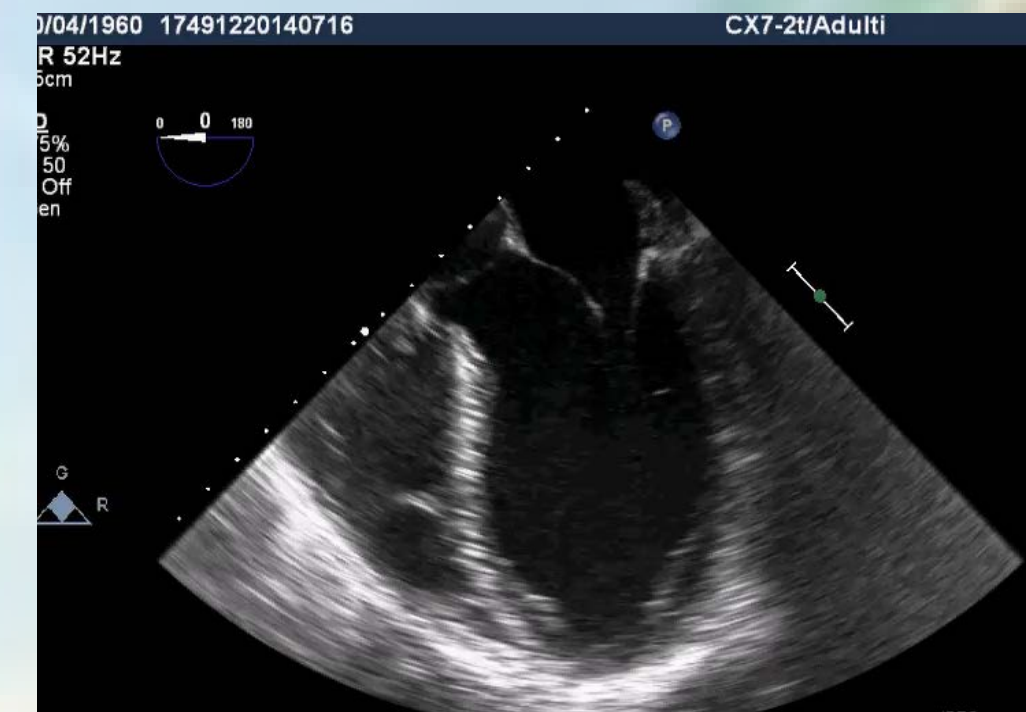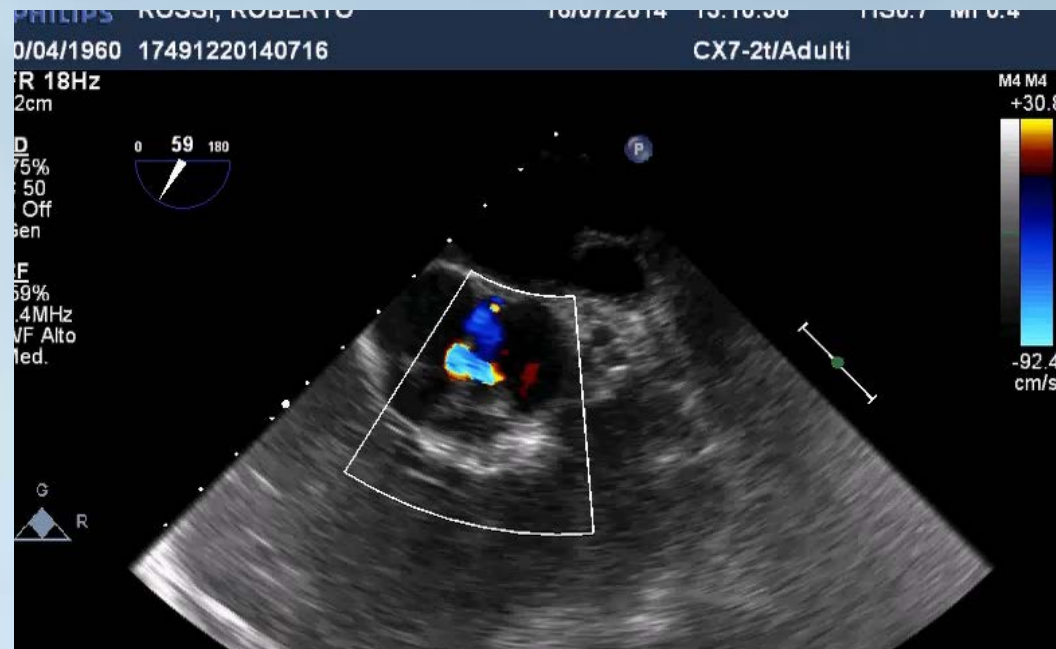
AMX Fighter

- right systolic murmur 2/6 2001
- Aortic regurgitation 2010
- aortic velocity 1.9 m/sec
- Mean $\Delta P < 20$ mmHg

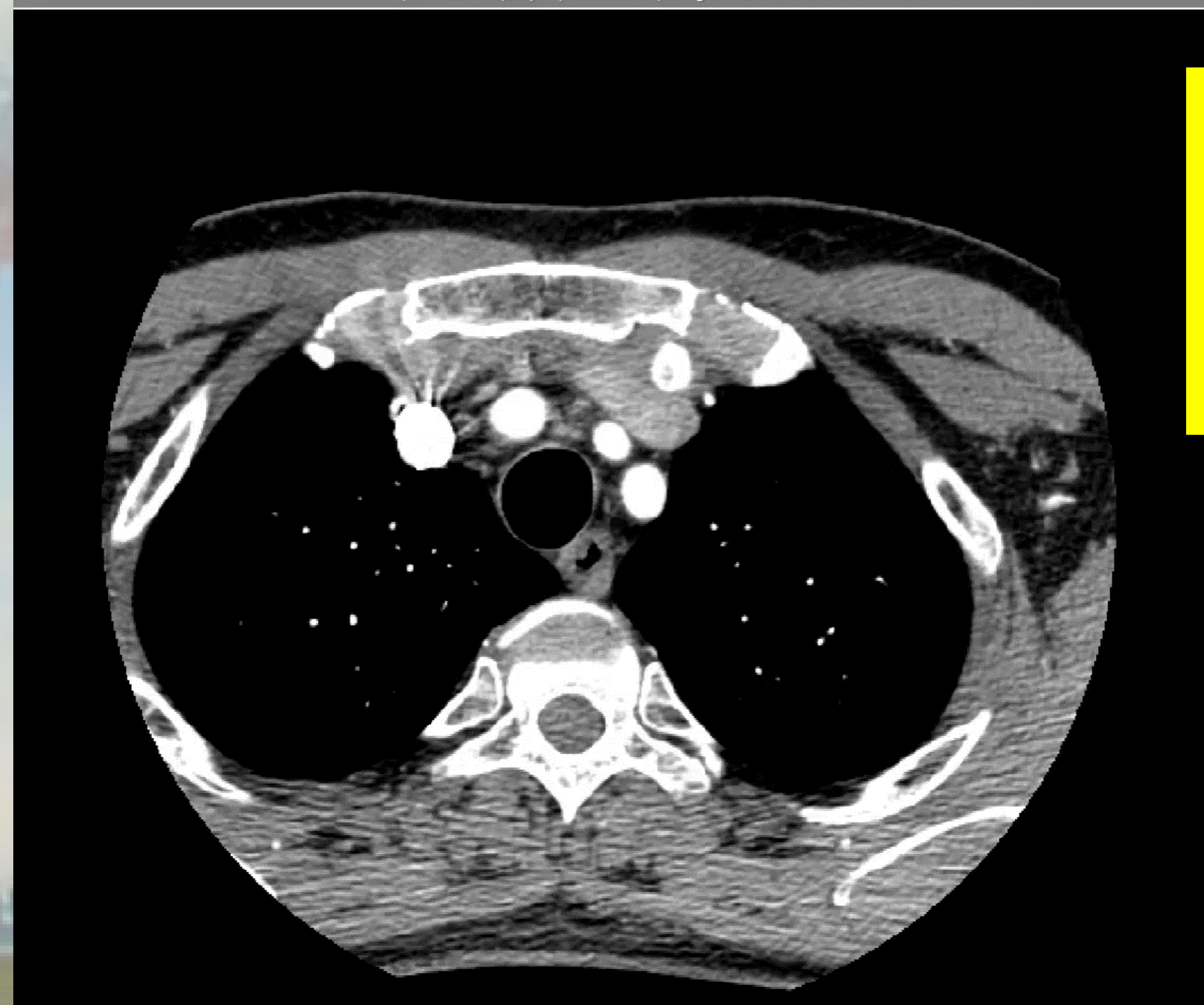


Clinical
case

#2



- BP=120/75
- HR=65/min
- BMI=23,1



MULTI PILOT

- symptomless
- silent
anamnesis
- male sex
- born 1960
- ACE2 -2015

Military Pilot #3

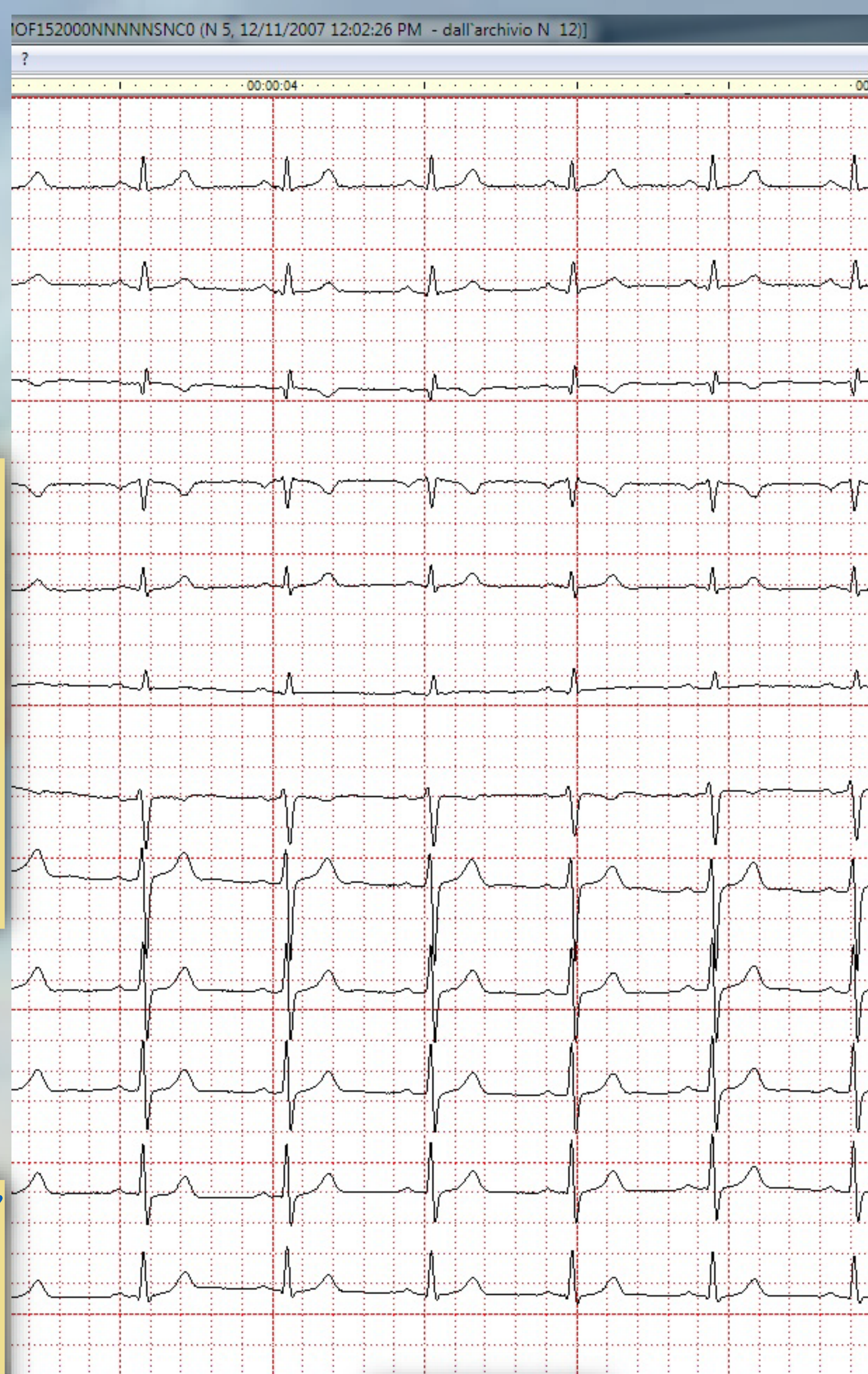
AW129



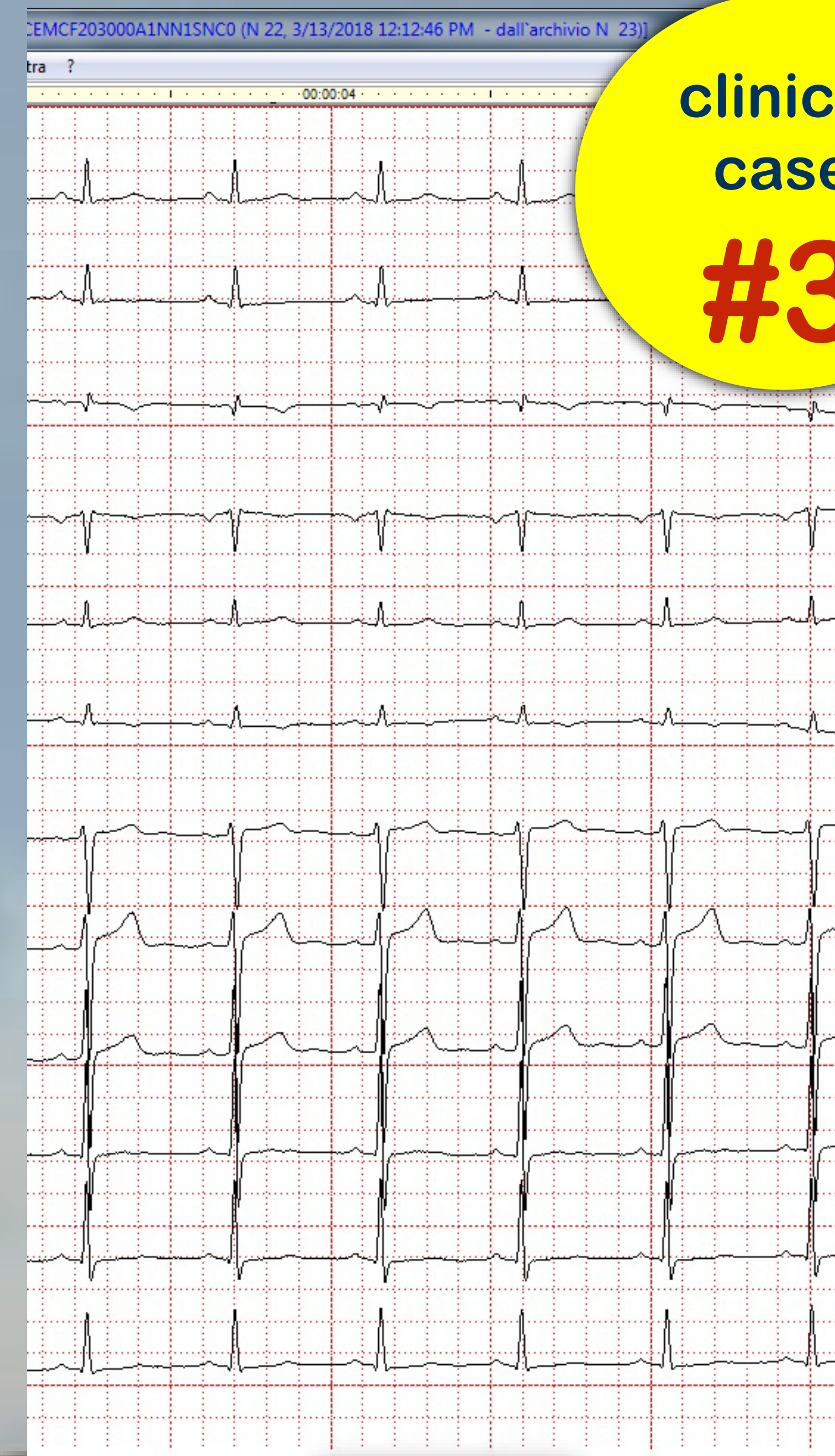
- No symptoms until 2018
- 2018 dizziness, pre-syncope
- previous AF 2009, hypertension 2009
- male sex
- born 1968
- ACE2, Amlodipine

- BP=130/85
- HR=85/min
- BMI=29,5

- right systolic murmur 2/6 2017
- diastolic murmur 2/6 Erb
- echo Aortic Regurgitation ++
- Aortic Velocity 3.0 m/sec



2007



2018

clinical
case
#3

Military Pilot #3 AW129



- No symptoms until 2018
- 2018 dizziness, pre-syncope
- previous AF 2009, hypertension 2009
- male sex
- born 1968
- ACE2, Amlodipine

NOT FIT

clinical case
#3

MULTI PILOT

- BP=130/85
- HR=85/min
- BMI=29,5

- right systolic murmur 2/6 2017
- diastolic murmur 2/6 Erb
- echo Aortic Regurgitation ++
- Aortic Velocity 3.0 m/sec

- 2009/2018 Exercise Test neg
- 2009/2018 holter ECG/MBP neg
- 2009 Aortic Vel < 2m/sec
- Fit with double command 2009
- Mean Ao Δ g 18mmHg 2015
- Mean Ao Δ g 39mmHg 2018

• MILD

• MODERATE

• SEVERE

- Mean Δ P < 20mmHg

- Mean Δ P 20-39mmHg

- Mean Δ P \geq 40mmHg

FIT

MULTI PILOT

NOT FIT

clinical
case

#3



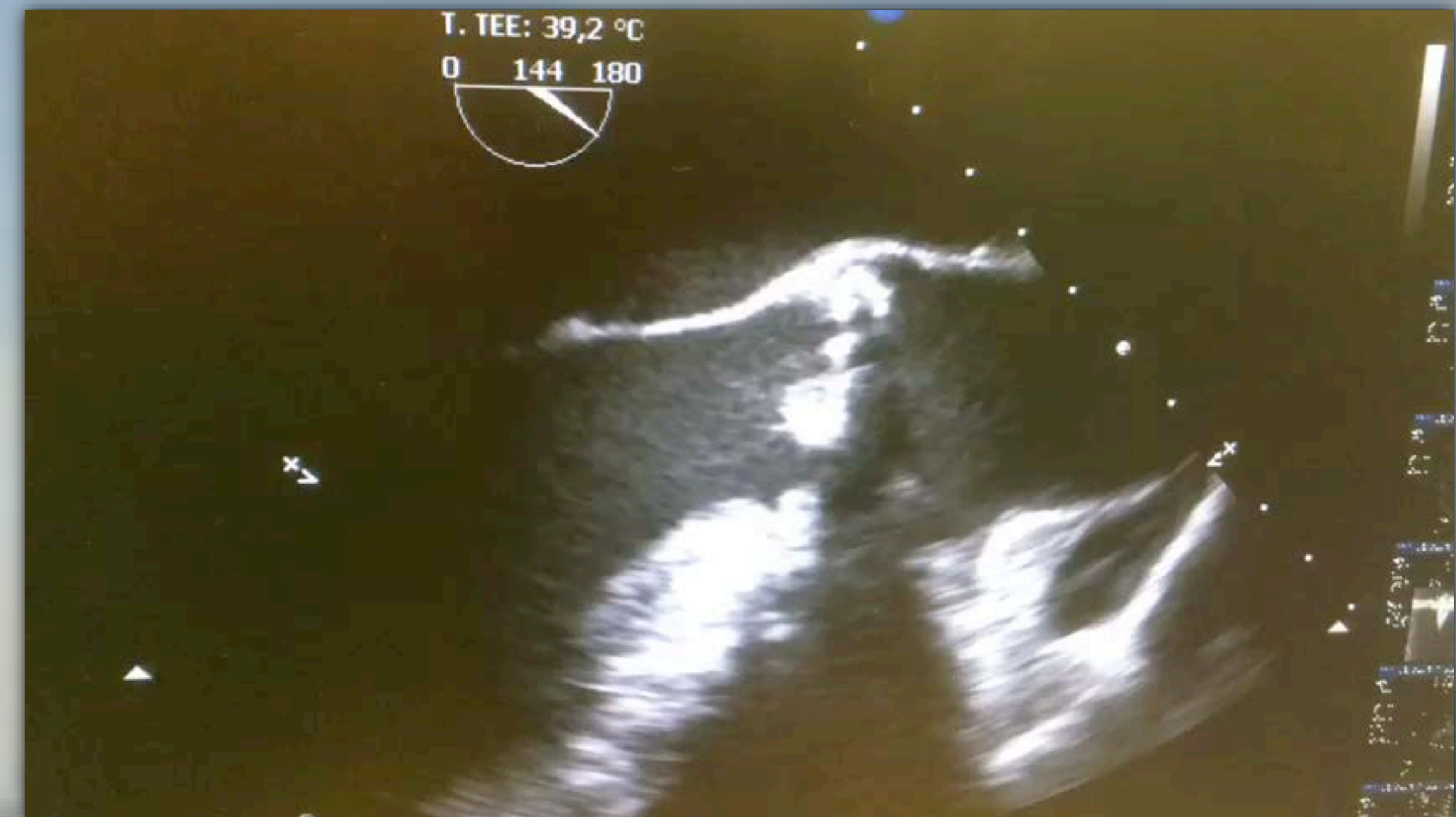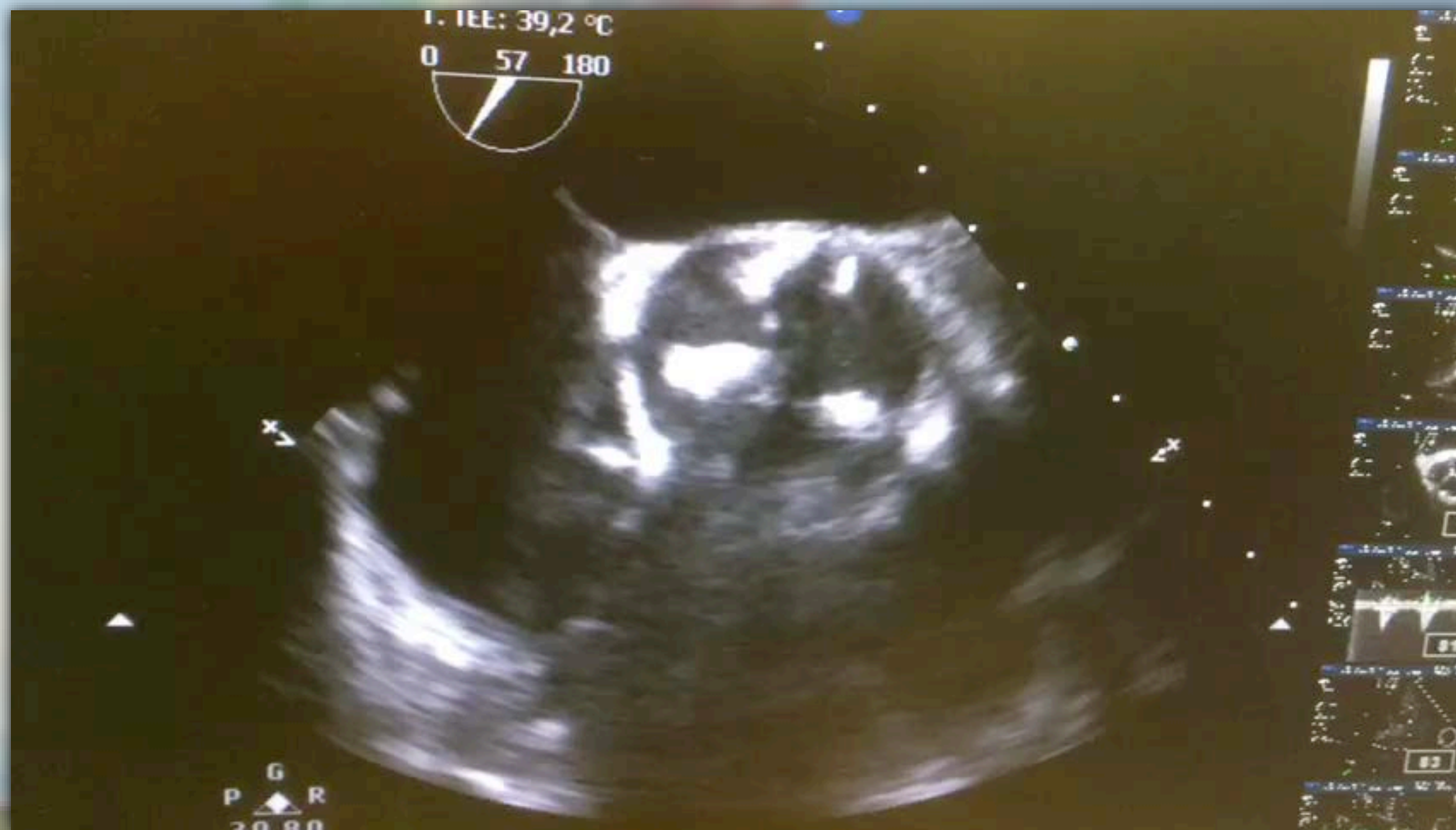Surgical images provided by
Prof.G.Polvani (Cardiac Surgery 2)
Prof. M Agrifoglio (Cardiac Surgery 2)
CC Monzino, IRCCS, Milan, Italy.



Military Pilot #3 AW129



UNIVERSITÀ
DEGLI STUDI
DI MILANO



Military Pilot #3

AW129



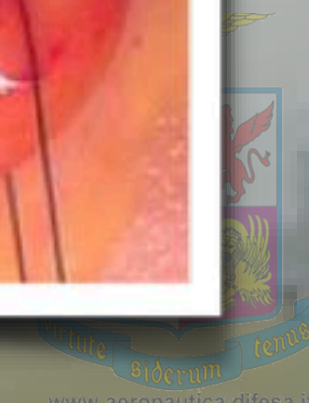
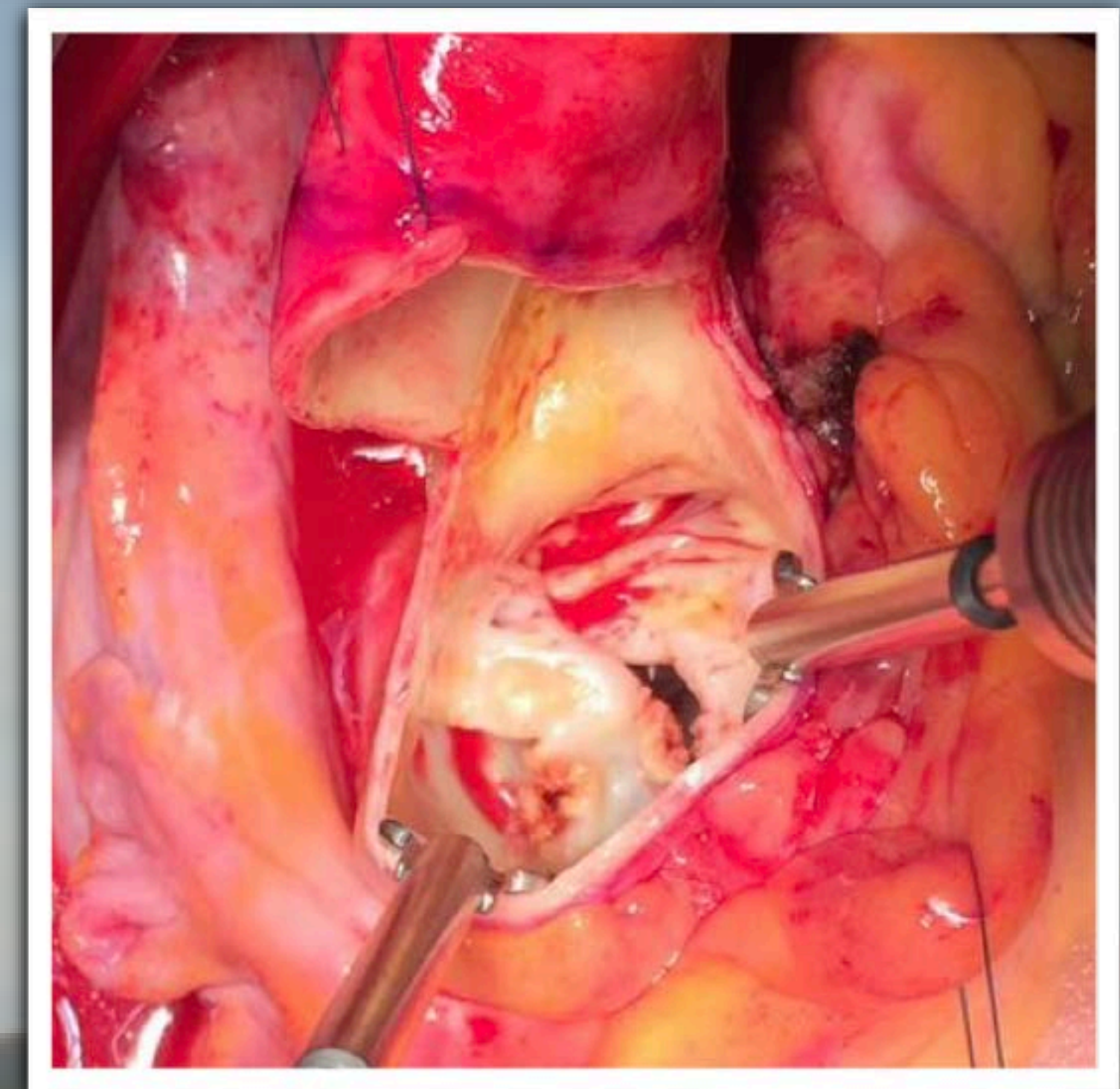
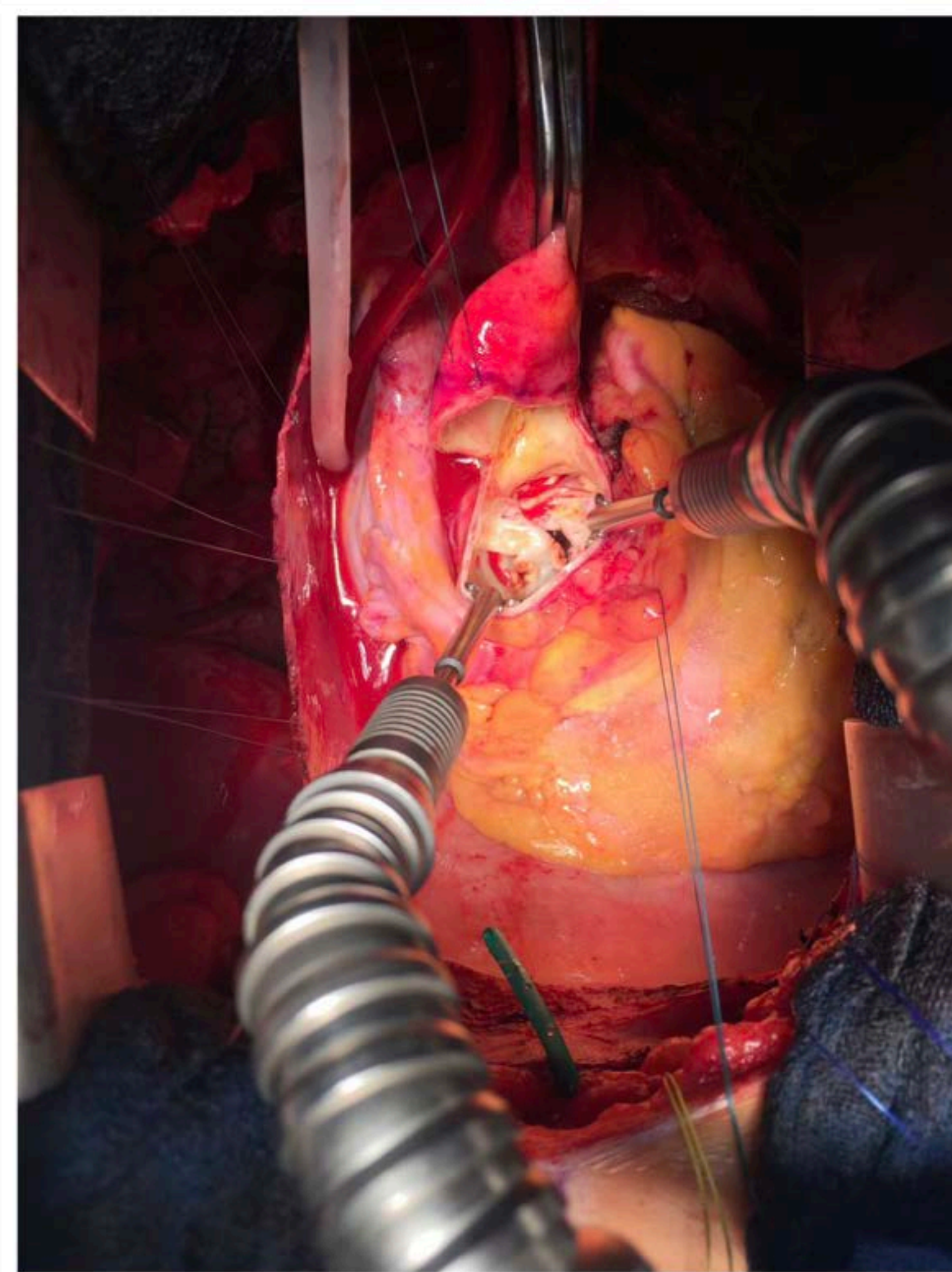
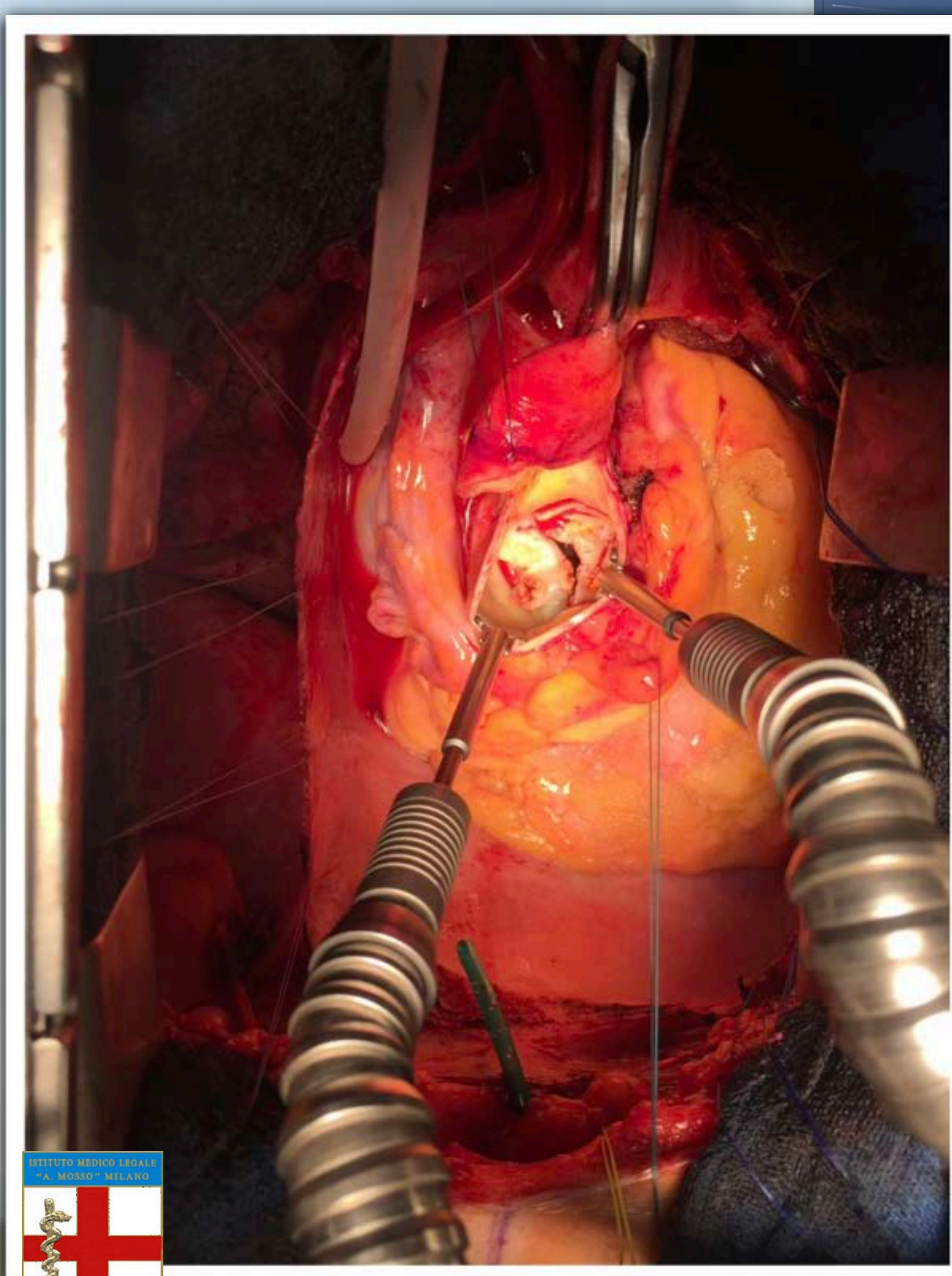
Surgical images provided by
Prof.G.Polvani (Cardiac Surgery 2)
Prof. M Agrifoglio (Cardiac Surgery 2)
CC Monzino, IRCCS, Milan, Italy.

Surgical procedure developed by the Japanese cardiac surgeon Shigeyuki Ozaki at the Department of Cardiovascular Surgery of Toho University, Ohashi Medical Center, Tokyo, - which allows the replacement of the aortic valve using, instead of the prosthesis, the patient's tissue.

clinical
case
#3



UNIVERSITÀ
DEGLI STUDI
DI MILANO



www.aeronautica.difesa.it

Military Pilot #3

AW129

Surgical images provided by
Prof.G.Polvani (Cardiac Surgery 2)
Prof. M Agrifoglio (Cardiac Surgery 2)
CC Monzino, IRCCS, Milan, Italy.




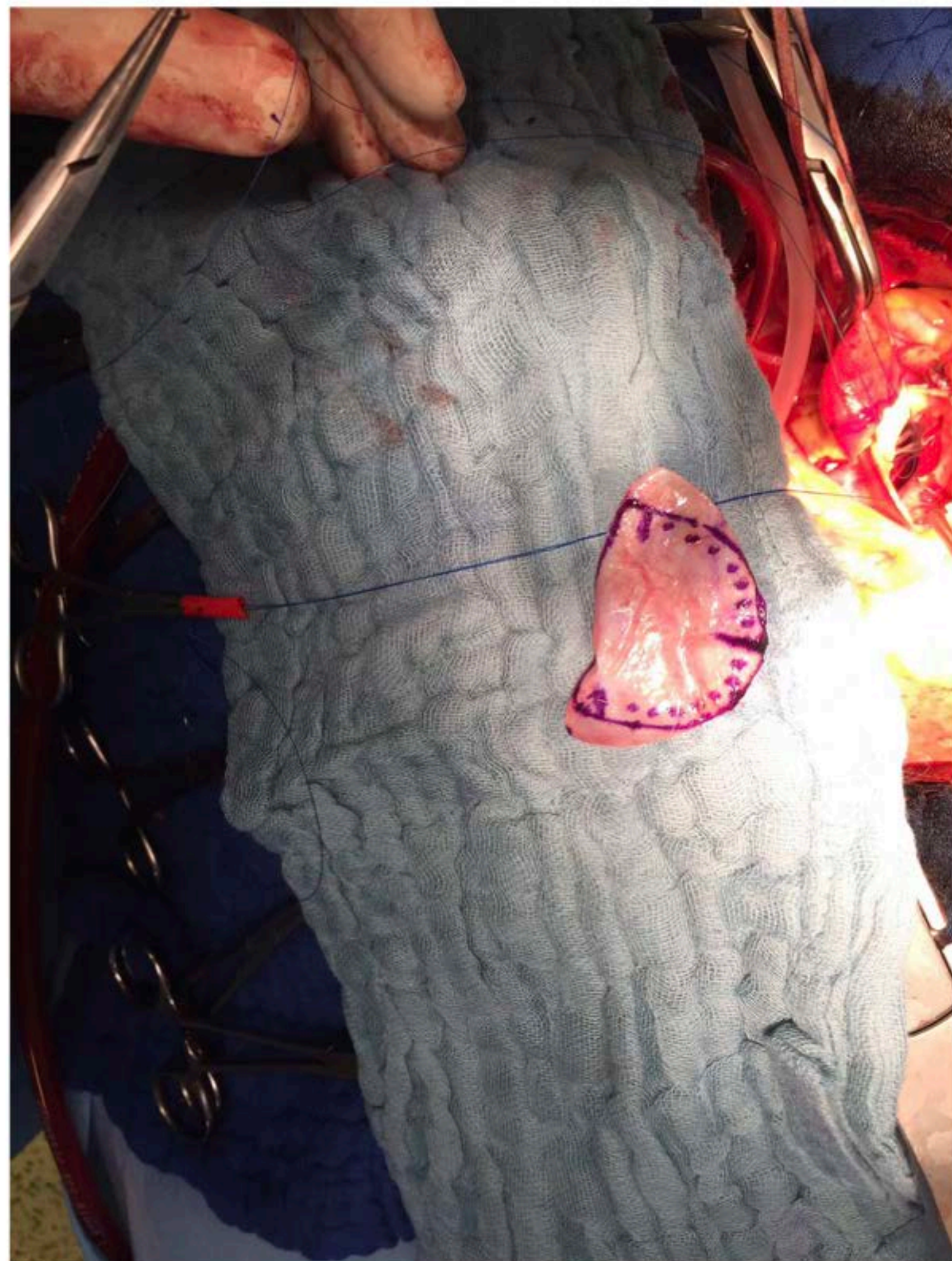
Centro Cardiologico
Monzino



UNIVERSITÀ
DEGLI STUDI
DI MILANO

clinical
case

#3



Surgical procedure developed by the Japanese cardiac surgeon Shigeyuki Ozaki at the Department of Cardiovascular Surgery of Toho University, Ohashi Medical Center, Tokyo, - which allows the replacement of the aortic valve using, instead of the prosthesis, the patient's tissue.



Military Pilot #3

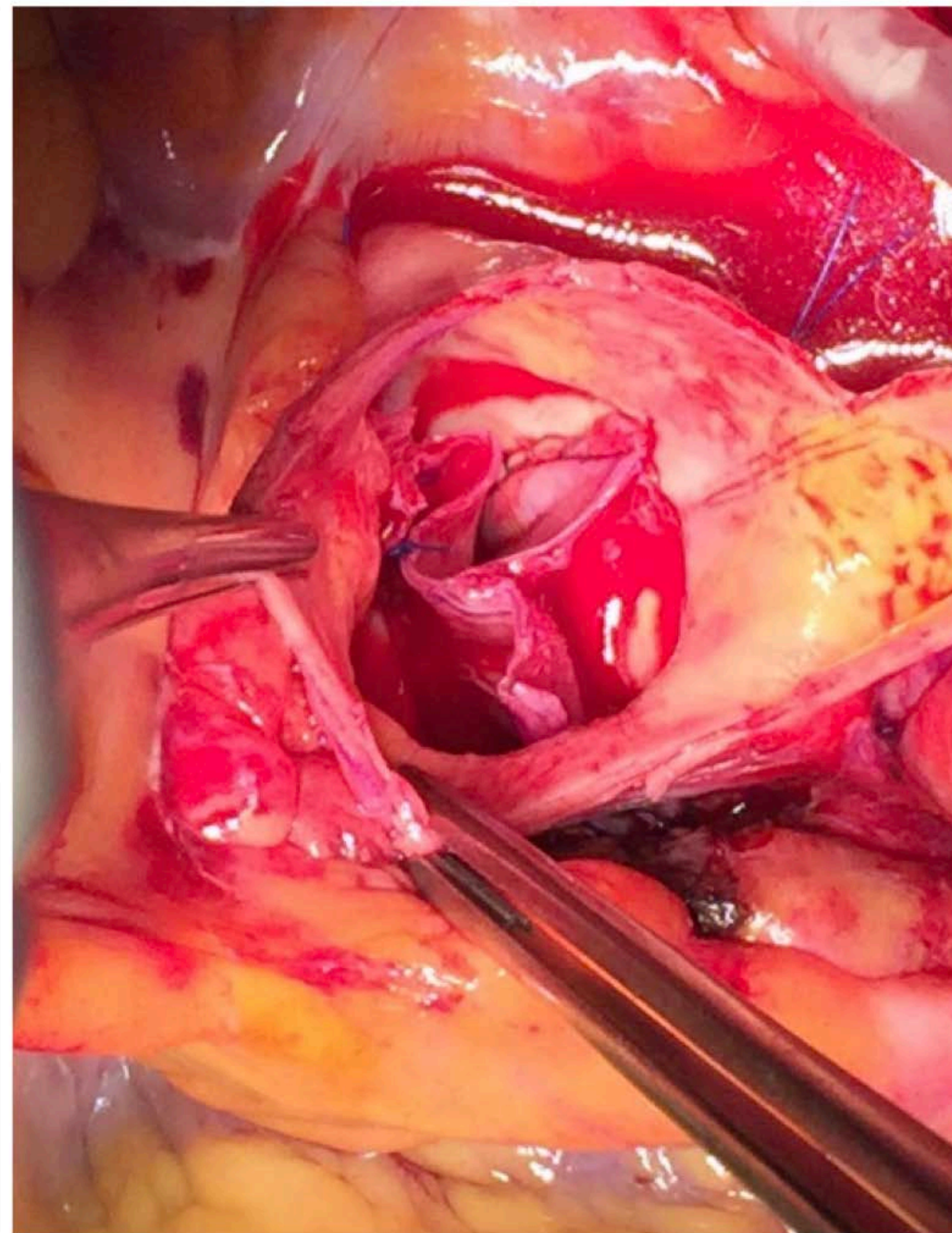
AW129



Surgical images provided by
Prof.G.Polvani (Cardiac Surgery 2)
Prof. M Agrifoglio (Cardiac Surgery 2)
CC Monzino, IRCCS, Milan, Italy.



UNIVERSITÀ
DEGLI STUDI
DI MILANO



clinical
case

#3

Surgical procedure developed by the Japanese cardiac surgeon Shigeyuki Ozaki at the Department of Cardiovascular Surgery of Toho University, Ohashi Medical Center, Tokyo, - which allows the replacement of the aortic valve using, instead of the prosthesis, the patient's tissue.

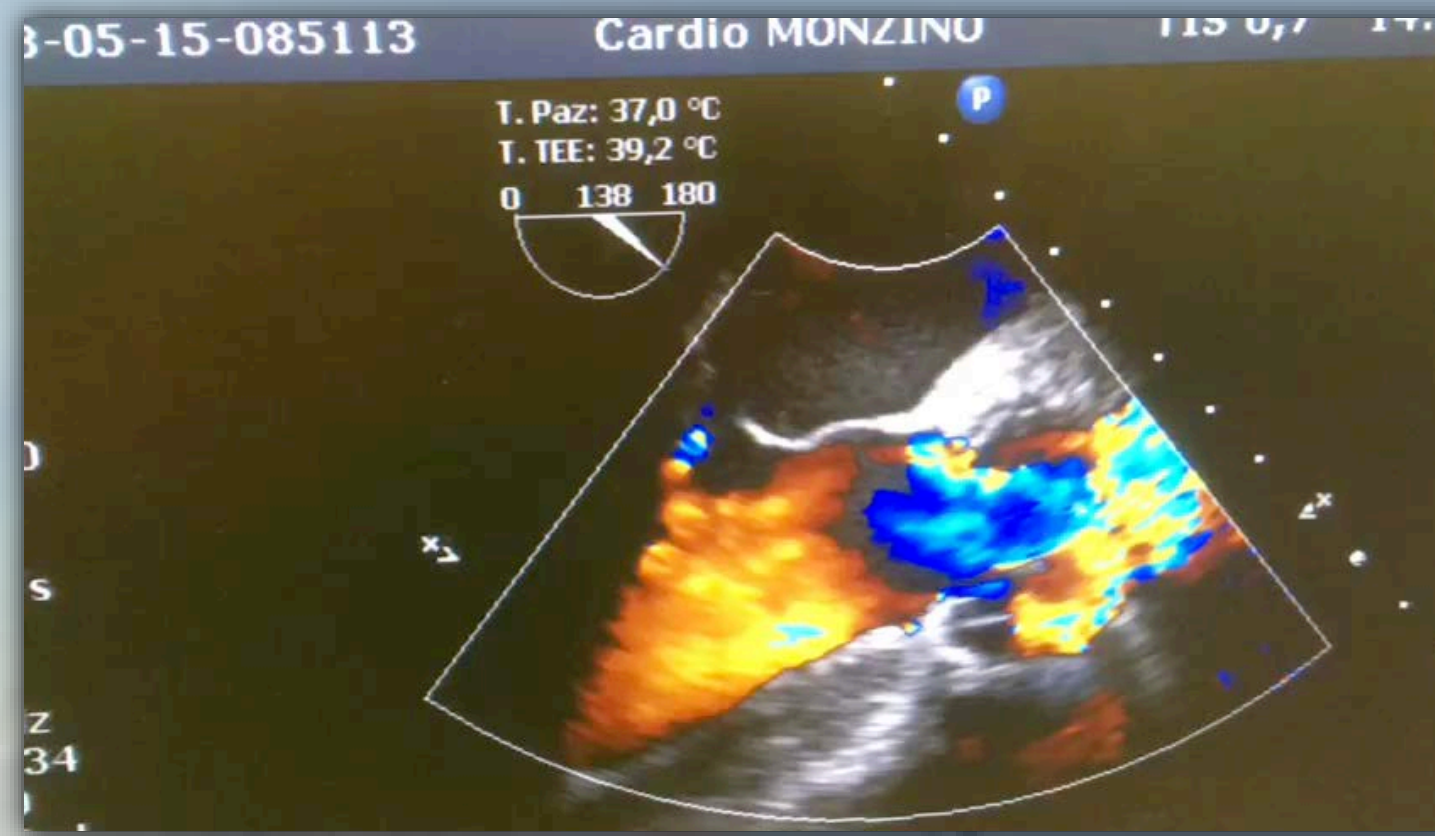


www.aeronautica.difesa.it

Military Pilot #3

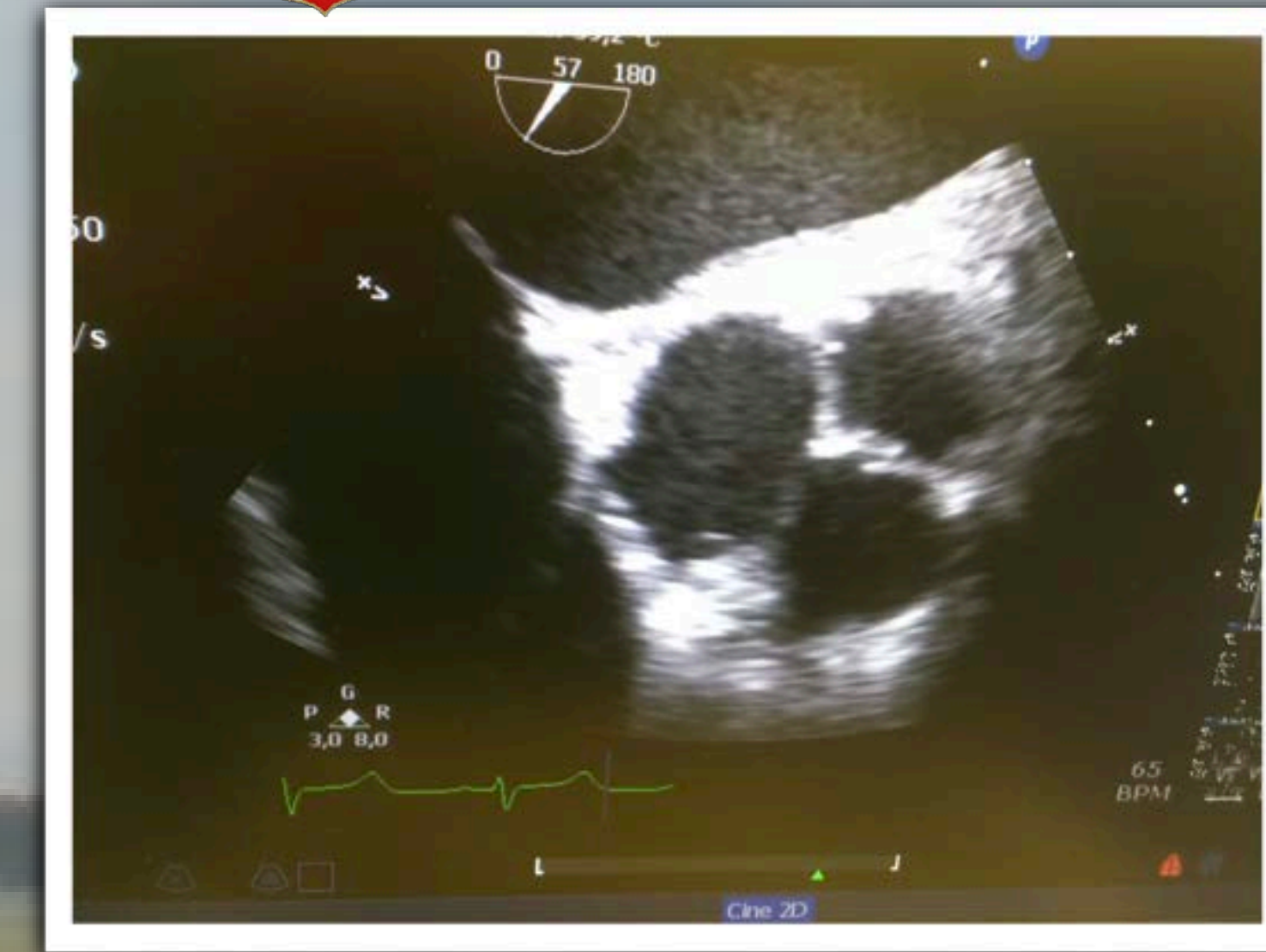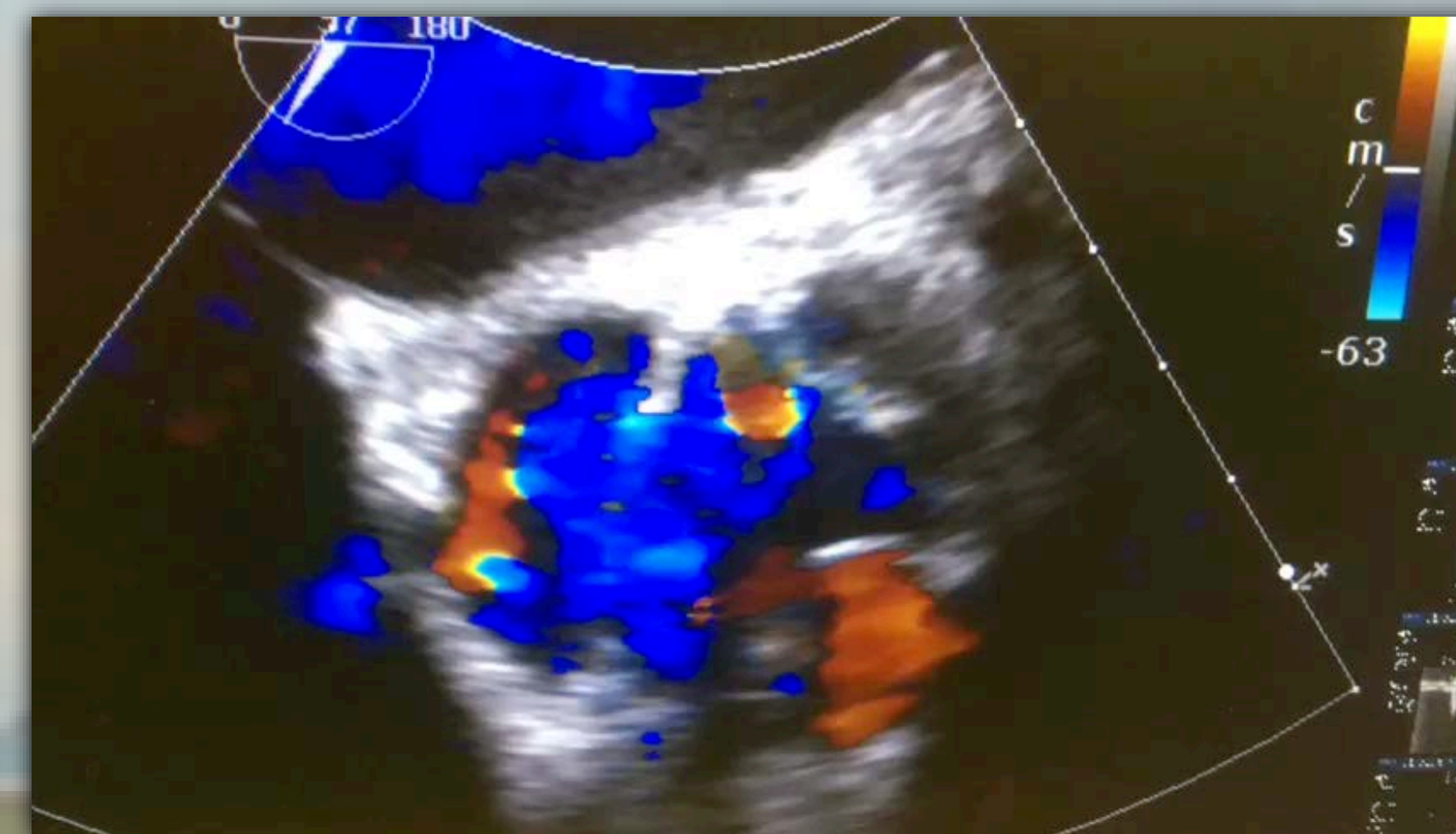
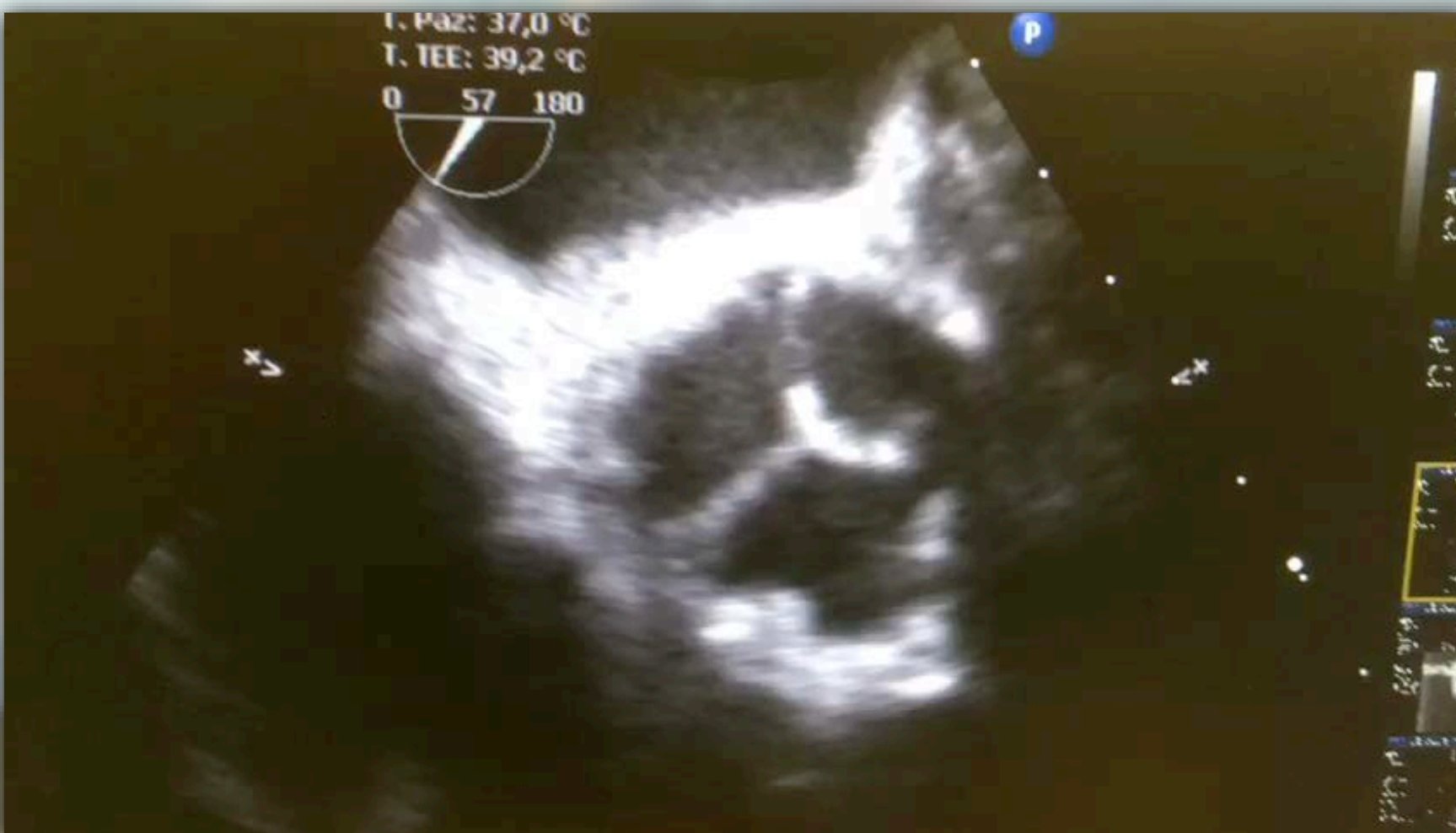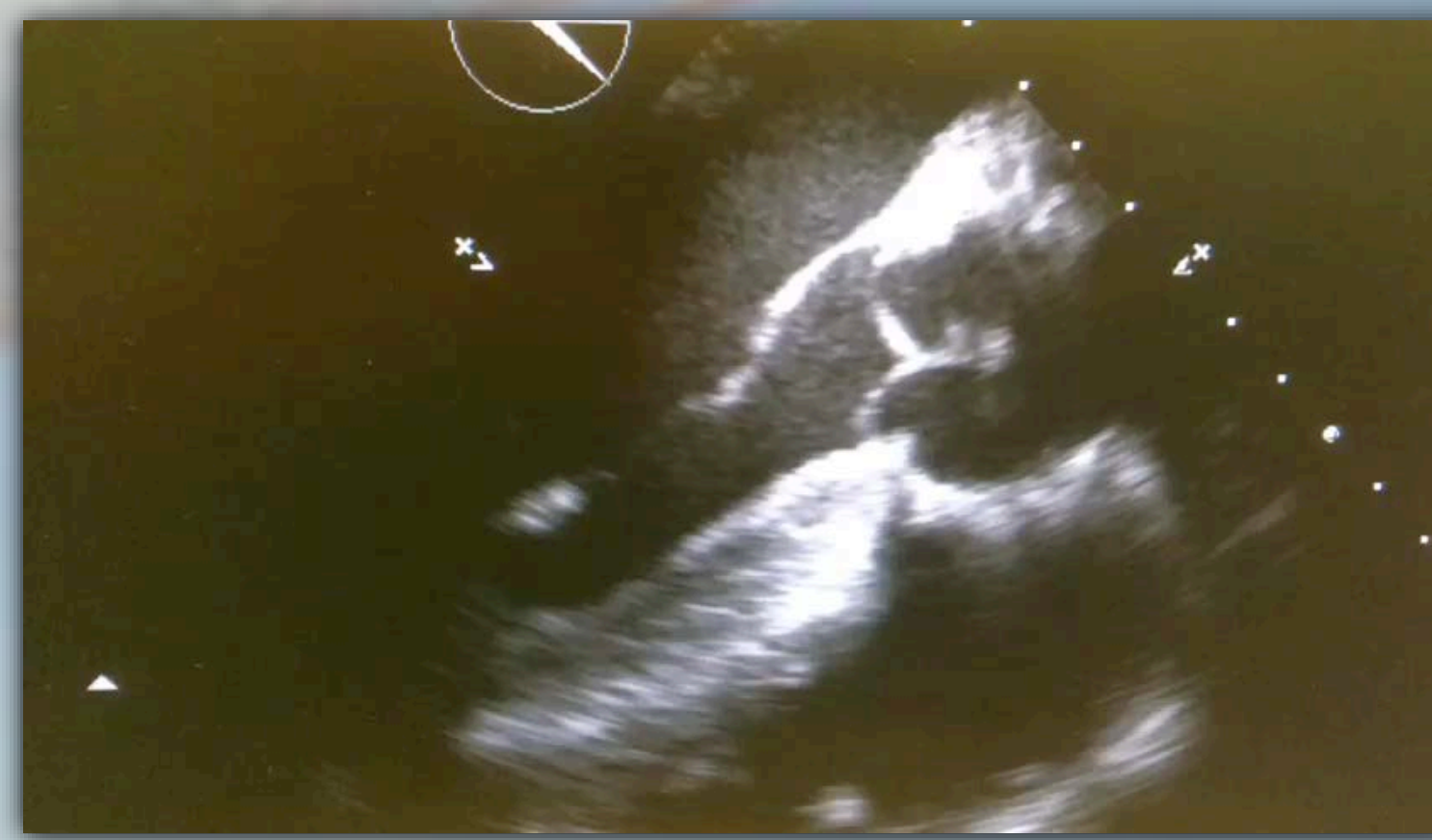
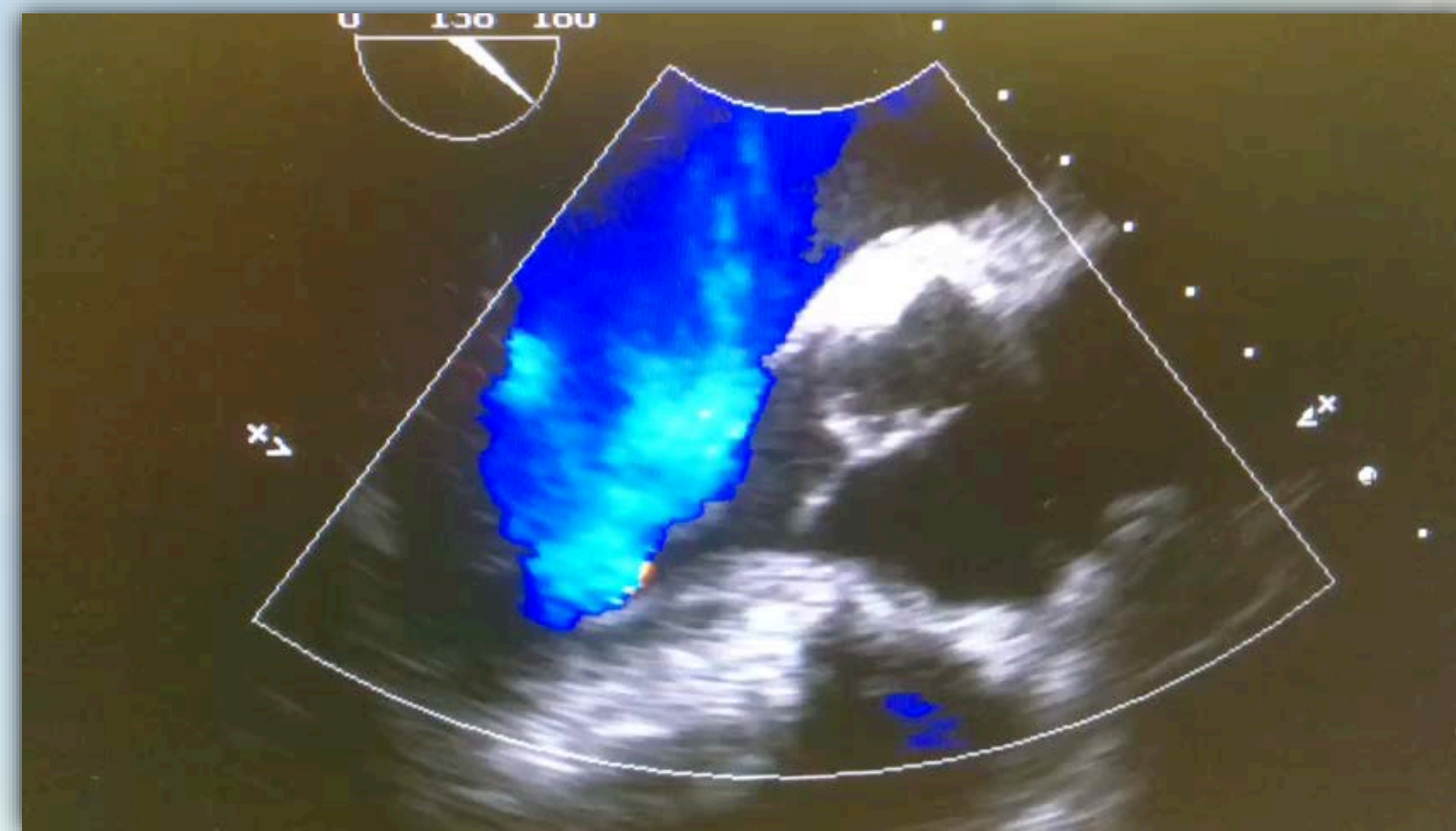
AW129

surgical images provided by
Prof.G.Polvani (Cardiac Surgery 2)
Prof. M Agrifoglio (Cardiac Surgery 2)
CC Monzino, IRCCS, Milan, Italy.



Surgical procedure developed by the Japanese cardiac surgeon Shigeyuki Ozaki at the Department of Cardiovascular Surgery of Toho University, Ohashi Medical Center, Tokyo, - which allows the replacement of the aortic valve using, instead of the prosthesis, the patient's tissue.

clinical
case
#3





In conclusion, Bicuspid Aortic Valve Disease:

- is the most common congenital heart disease
- it can be hereditary
- should be suspected in the presence of an aortic systolic murmur
- due to the high incidence of complications a follow-up is recommended especially in military flight crews
- when valvular surgery is the choice a good option is represented by autologous pericardium.



Thank you.

Lt.Col. Fabrizio Palumbo

fabrizio.palumbo@aeronautica.difesa.it

fabriziopalumbo@libero.it



Remember that the best doctor is nature: it heals two-thirds of the diseases and does not talk bad of the colleagues.

Galen, 200 AC

fabriziopalumbo@aeronautica.difesa.it





www.aeronautica.difesa.it